

LINCOMYCIN TOXICITY IN FARM RABBITS: REPORT ON A SEVERE CASE

Joan Maria Rosell¹*, Ricard Garriga²†, Jordina Casas³†, Natàlia Majó^{1,2,3}‡§, Jaume Alomar¹§

*Cunivet Service. P.O. Box 518, 43080 TARRAGONA, Spain.

†Federació d'Associacions de Cunicultors de Catalunya (FACC). Carrer Ull de Llebre, 13 08734 OLÉRDOLA, Barcelona, Spain.

‡Institut de Recerca i Tecnologia Agroalimentàries (IRTA)-Centre de Recerca en Sanitat Animal (CRESA), Campus de la Universitat Autònoma de Barcelona, 08193 BELLATERRA, Barcelona, Spain.

§Departament de Sanitat i Anatomia Animals, Facultat de Veterinària, Universitat Autònoma de Barcelona, 08193 BELLATERRA Barcelona, Spain.

Abstract: In this study, we describe a case of severe toxicity by lincomycin contamination in feed on a farm housing 1800 rabbit does. The farm used a two-batch system, with parities 24 and 3 d ago, respectively. The rabbits that had consumed the feed developed anorexia 24-48 h later, followed by enteritis-diarrhoea and death. Mortality was >70% in does, >50% in 28-day-old kits. None of the 7-day-old kits died from this cause. A total of 125 non-lactating does that had consumed another type of feed from the same supplier were not affected; 10 of them were given the contaminated feed and the same problem occurred. Treatment based on presumptive diagnosis was unsuccessful. Microbiological and histopathological studies identified *Clostridium spiroforme*, which predominated over coliform bacteria. Toxicology studies requested by the producers verified the existence of 1.6 ppm amoxicillin in the first place; weeks later, further analyses determined 410 ppm lincomycin in doe feed. It also contained the prescribed quantity of 199 ppm tilmicosin. We recommended the stamping-out on the farm.

Key Words: animal welfare, *Clostridium spiroforme*, lincomycin, rabbit, toxicity.

INTRODUCTION

Digestive diseases of farmed rabbits account for 49% of urgent farm visits by vets (Rosell *et al.*, 2009). The aetiology of digestive disorders in rabbits is often complex (Peeters *et al.*, 1984). Although the aetiopathogenesis of Epizootic Rabbit Enteropathy (ERE; similar to mucoid enteropathy) is unknown, *Clostridium spiroforme* is not related to it (Marlier *et al.*, 2006). Antimicrobials and other medicines are used to control some digestive disorders in rabbits. Due to difficulties encountered in treatment, such as the highly complex aetiology (Agnoletti, 2012), antimicrobial resistance of bacteria (EFSA, 2021) and, finally, the restricted use of antimicrobials, preventive measures have been reinforced on farms.

Some antibiotics are harmful to rabbits because they produce changes in the intestinal microbiota, with the proliferation of *Escherichia coli* or *Clostridium* spp. such as *C. spiroforme* (Licois, 1996). Rabbit females at peak lactation are predisposed to intoxication via feed as they ingest >400 g/d (Lebas, 2020). External factors enable intestinal dysbiosis, as do some antibiotics. For example, amoxicillin or penicillin are toxic when administered orally, but less so parenterally. These and other molecules were administered parenterally at parturition on 70% of farms (Rosell and de la Fuente, 2018). Lincomycin is another example; orally administered alone, it causes gut dysbiosis in

Correspondence: J.M. Rosell, jmrosell@cunivetservice.com. Received December 2021 - Accepted May 2022.
<https://doi.org/10.4995/wrs.2022.16819>

Cite as: Rosell J.M., Garriga R., Casas J., Majó N., Alomar J. 2022. Lincomycin toxicity in farm rabbits: report on a severe case. *World Rabbit Sci.*, 30: 147-152. <https://doi.org/10.4995/wrs.2022.16819>

rabbits (Gray and Lewis, 1966). In our practice, low doses of soluble lincomycin associated with spectinomycin were orally administered in weaned rabbits to control ERE (1 and 2 mg/kg body weight/d, respectively, 5 d), subcutaneously in lactating does (5 mg and 10 mg/kg body weight, single dose, respectively). Fesce *et al.* (1977) used it via the oral route combined with other molecules such as gentamycin.

In meat rabbits, Thilsted *et al.* (1981) observed an adverse effect caused by feed contaminated with 8.4 ppm lincomycin, which also contained undetermined doses of penicillin. They isolated coliforms from caecal samples. With regard to disorders caused by antibiotics, clostridial enterotoxaemia is often observed in sick rabbits (Fisher and Graham, 2018), e.g., due to the proliferation of *C. spiroforme* and its toxins (Carman and Borriello, 1984). In 2006, there was a serious case of intoxication in does via feed containing 300 ppm of lincomycin (Rosell and de la Fuente, 2016). Six years later, we visited an insemination centre where a second episode of lincomycin contamination in feed had taken place.

Our objectives were to describe an outbreak of lincomycin toxicity in rabbit feed in January 2021, (1) explaining the process followed for interpretation of the case, and (2) showing the results of the field and laboratory work carried out.

MATERIALS AND METHODS

The farm and affected does

Our study comprises the period between 5th January and 3rd July, 2021. The farm housed 1800 breeding does, 100 of which were maternal pure line to obtain the crossbred does for replacement. They were distributed in two independent barns, each with a single batch. The barns were equipped with mechanical ventilation as well as heating (minimum temperature: 18°C, when it reached -5°C outdoors) and cooling (maximum temperature: 29°C, when it reached 37°C outdoors). Drinking water was chlorinated. The does were served by insemination 11 d postpartum, with 21 d difference between the 2 barns. Semen was obtained from an external supplier, who we visited once a year. Kits were weaned at 32-33 d and moved to another two buildings.

The problem began on 31st December, 2020, after the does had been fed. In one barn, there were 740 does with parities 24 d previously and in the other, 589 parities 3 d previously. Two days later, farm staff noticed that they had stopped eating; the following day, losses began to occur. The supplier's veterinary team were informed and took charge of the situation. They also decided to withdraw the feed. Our work began on the 5th January after receiving notification of the problem, and we visited the farm over the course of 6 mo.

Description of the problem

The first deaths occurred on 4th January: a total of 8 does from the two barns and 150 kits in one barn with 740 lactating does and 6700 kits in 28 d. In the other barn, no losses occurred amongst the 7-day-old kits. A large number of does in both barns were affected; they developed anorexia, prostration and enteritis-diarrhoea. Kits that consumed the feed became sick, except for the 7-day-old ones; unlike other episodes in previous years, none of the kits of sick does developed enteritis. On 5th January, we found a total of 48 females and over 286 29-day-old kits. On the 6th, 111 does, 45 of which were on the 9th day of lactation, >500 of the 5500 kits in this barn died of inanition. By 19th January, the problem in does had been alleviated; there were fewer than 500 does left.

Diagnostic procedures used on the farm

Different types of feed from the same supplier were used on the farm. In the barn housing 740 24-day-old lactating does, 125 non-lactating does were set apart and manually given another type of feed. None of these does died, and feed consumption was normal. This is what made us suspicious of the food. The following objective was to focus on the feed. Our main hypothesis was crossed contamination with a beta-lactam antibiotic.

Sample collection and analysis

On 5th January, we necropsied the acute cases. Lesions were found mainly in the digestive tract. Macroscopic examination confirmed a full stomach and haemorrhagic typhlitis (Figure 1a). Transmural wall thickening, with detachment of the mucosa and moderate, slightly reddish liquid content were observed in the caecum (Figure 1b). We took samples of the caecum, liver and kidney of lactating does and kits for histopathological study; they were fixed in 10% buffered formaldehyde for 48 h and sent to the *Servei de Diagnòstic de Patologia Veterinària* (SDPV) at the *Universitat Autònoma* of Barcelona Veterinary Faculty. The samples were routinely processed using alcohol and paraffin baths and then cut into 3 µm sections, stained with haematoxylin and eosin (HE) and Gram staining.

The first samples for microbiological testing were sent on 5th January by the supplier. On 11th January, we sent caecal samples from does that had developed diarrhoea to a Microbiology laboratory (Exopol) and the analysis techniques used were described by Solans *et al.* (2019); concerning Real-Time PCR, they used detection with EXOone qPCR kits, considering a sample positive if it had a Cq value ≤ 38 . In addition, we sent samples from kits and females to another laboratory, also for microbiological testing (Analítica Veterinària). They were tested using cultures: blood agar and MacConkey agar under aerobic and anaerobic conditions, as well as selenite broth and *Salmonella-Shigella* agar in aerobiosis; lastly, Gram staining for *C. spiroforme*. The first feed samples were taken from the feed distribution tubes. The Agrolab Ibérica group carried out an analysis for amoxicillin in the first two batches of samples. The third analysis was to determine the presence of tilmicosin; the prescribed dose was 200 ppm. The fourth and fifth analyses were to determine the presence of lincomycin. All analyses were performed in this laboratory or by collaborating laboratories, using accredited techniques. Tilmicosin was determined by high-performance liquid chromatography with Diode-Array Detection and lincomycin was determined by liquid chromatography-mass spectrometry.

RESULTS AND DISCUSSION

Analyses carried out

There was no microbial identification in the case of the first sampling. Exopol provided us with results for the Real-Time PCR test on the second batch of samples in 24 h: *E. coli* positive (Cq 28), but *eae* gen negative, *C. spiroforme* positive (bacterial bodies, excluding toxins, with Cq=22) and *Clostridium perfringens* negative. The results from Analítica Veterinària included mainly *E. coli*, followed by *Enterococcus gallinarum* and, lastly, *C. spiroforme* for the does, and mostly *Enterococcus* spp. and *C. spiroforme*, for the 37-day-old kits. Mixed isolations of enterobacteria, clostridia, *Eimeria* spp. (including *E. magna* and *E. media*, pathogenic species, among others) or rotavirus are frequent on affected farms (Peeters *et al.*, 1986), although age is an influencing factor; e.g., Solans *et al.* (2019), found few *C. spiroforme* isolations in kits <15 d old with enteropathy.

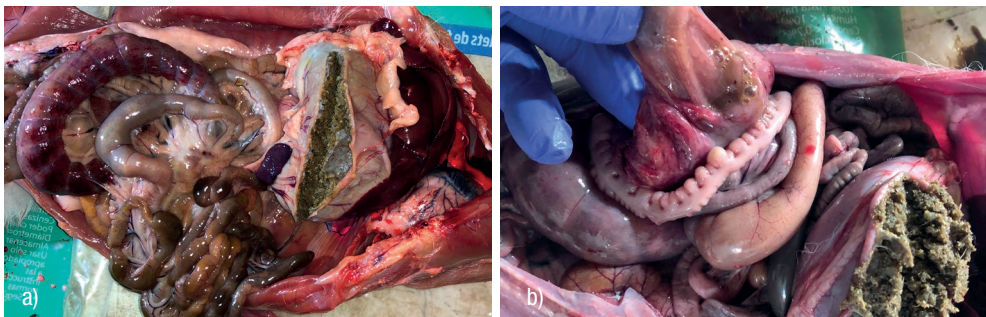


Figure 1: Post-mortem findings in does that ingested feed containing 410 ppm lincomycin. a) full stomach and haemorrhagic typhlitis. b) caecal mucosa and contents.

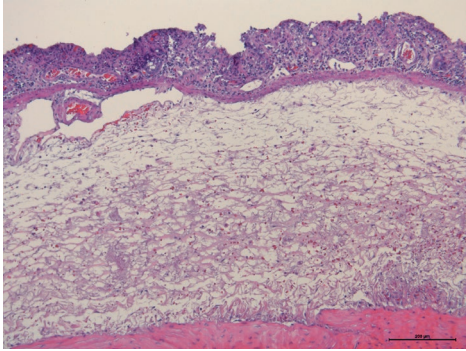


Figure 2: (HE 10X) Caecal section with necrohaemorrhagic typhlitis, with loss of mucosa, intense oedema and submucosal haemorrhage.

available). Lafargue-Hauret *et al.*, (1994) demonstrated that 2 ppm amoxicillin resulted in refusal to eat and enteritis. However, in another severe case in 2005 (Figure 5b), on that occasion due to amoxicillin administered in water, coliforms were isolated. In relation to the current case, on 7th January, does and kits were given feed containing 14.5% protein and 20% crude fibre treated with 100 ppm apramycin (5d), based on the presumptive diagnosis; they were also administered a liver protector supplement in oral solution (3d). According to Morisse *et al* (1989), 8 tons of feed with 1.6 ppm amoxicillin could cause damage, but contamination was small-scale and difficult to explain in such a large amount of feed; it seemed reasonable to consider the possibility of another toxic element. The third analysis was to determine the presence of tilmicosin; the feed contained the prescribed amount: 199 ppm. The fourth and fifth analyses were to determine lincomycin. In the fourth analysis, the amount of lincomycin exceeded the expected trace level. In the fifth, 410 ± 100 ppm lincomycin was found.

Evolution of the problem

Presumptive treatment against coliform bacteria with apramycin was not effective. This, together with absence of enteritis in 7-day-old kits and the first microbiological results, pointed to clostridiosis caused by *C. spiroforme*. Agnoletti *et al* (2009) showed that this pathogen was resistant to different antimicrobials, including sometimes lincomycin. Le Guennec *et al* (2007) tested 31 isolated kit strains and only found sensitivity to orally administered zinc bacitracin and tiamulin. Doxycycline would be an antimicrobial of choice according to the Istituto Zooprofilattico Sperimentale delle Venezie (EFSA, 2021). Clostridiosis by *C. spiroforme* occurs as a result of previous treatments, as indicated by

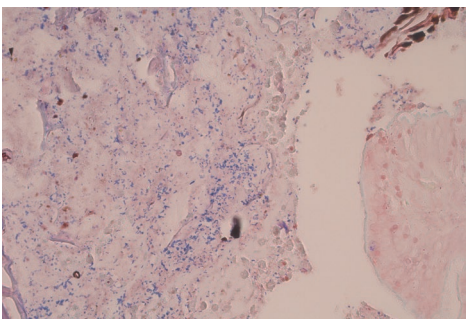


Figure 3: (Gram-stain 40X). Ileum with multiple spiral-shaped structures and Gram- positives intermixed with contents.

Intense haemorrhagic and necrotic typhlitis were predominant in the histopathological study. Nearly total loss of the mucosal layer, replaced by lytic necrosis, fibrin, degenerate cells, haemorrhage, a considerable amount of viable and degenerate heterophil cells, were observed. The deepest layers of the *lamina propria* presented a few blood vessels with vasculitis and hyaline degeneration in the vessel wall. Intense interstitial oedema with moderate haemorrhage was observed in the submucosa (Figure 2). Gram staining revealed moderate presence of Gram-positive spiral-shaped bacilli in the intestinal contents; some were adhered to the surface of the area of lytic necrosis, compatible with *C. spiroforme* (Figure 3).

The feed contained 1.6 ppm amoxicillin. In 1997, we attended a case of severe amoxicillin toxicities (4 ppm in feed) on a farm housing 1400 does; *C. spiroforme* was identified in the laboratory (results not presented, but

Glenn Songer and Uzal (2016). We did not resolve the serious problem; in fact, we probably made it worse, in accordance with Harkness *et al.* (2010). Does and kits died over a period of 15 d. In the control of enteropathies on farm rabbits, we use different technical and financial criteria to those used for pet rabbits. In a sick individual, other supportive therapy is used; if it is timely, it has a favourable prognosis (Harcourt-Brown, 2002). Also, some molecules are effective against enterotoxaemia caused by *C. spiroforme*, such as dimetridazole, described by Whitney (1974), or metronidazole (Oglesbee and Lord, 2021), but they are not authorised in meat rabbits.

A trial was carried out on the affected farm in mid-February. Two groups of 10/125 does that had not had contact with the test feed were housed individually. One

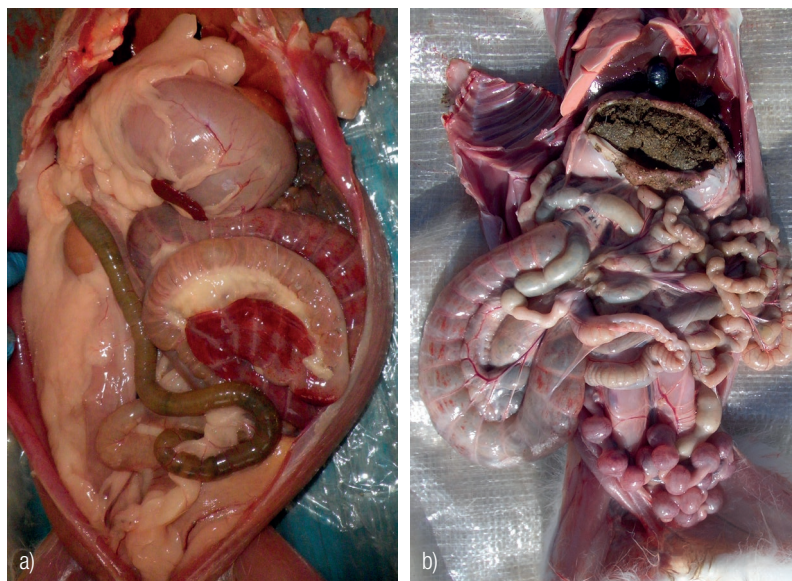


Figure 5: a) post-mortem findings in a buck (left) that died after ingesting lincomycin in feed. b): a doe intoxicated by amoxicillin in water.

group was given normal feed and the other test feed. Again, they stopped eating and 10 d later only 6 does with cachexia remained; we decided to end the test for animal welfare reasons. The dead does had the same lesions as those observed when the problem arose. We took samples from their feeders and tested for tilmicosin and lincomycin.

Interpreting the problem

Six months after the onset of the problem, now technically resolved, and having formalised an agreement between the parties, our perspective is as follows. Firstly, it was severe for the rabbits. It was also a very hard situation for the farm staff, who had to cope with seeing sick rabbits non-stop for 15 d and culling >4000 orphaned kits. We recommend that surviving does also be culled. Experience of previous cases has shown us that opportunistic pathogens (*Staphylococcus aureus*, *Pasteurella multocida*, amongst others), thrive in survivors, probably because their immune system breaks down.

Concerning the presumptive diagnosis, we attach images of a buck that died after ingesting lincomycin in the feed (Figure 5a) and a doe that had ingested amoxicillin in water (Figure 5b). Haemorrhagic typhlitis was observed in both cases, compatible with clostridiosis and colibacillosis, respectively. The lesions were macroscopically similar, as shown by Licois (2009).

Based on experience in beta-lactam antibiotics or lincomycin toxicity in farm rabbits, the macroscopic lesions observed were similar. Therefore, diagnosis needs to be complemented by microbiological, histopathological and toxicological analyses, among others. According to our experience, the prognosis for toxicities due to ingestion of lincomycin, with enterotoxaemia caused by *C. spiroforme* on rabbit farms, is guarded.

CONCLUSIONS

This is a retrospective study of a case of toxicity on a commercial rabbit farm housing 1800 does that were given feed contaminated with 410 ppm lincomycin. Viability in the rabbits that ingested the contaminated feed was less than 50%. They died due to gut dysbiosis and *Clostridium spiroforme*-mediated enterotoxaemia, which was predominant by comparison with other bacteria. Treatment was ineffective and rabbits died over the course of 15 d. The 7-day-old

kits, born to does with enteritis-diarrhoea, were not affected by enteritis; they developed inanition. In our experience, cases of toxicity by feed contaminated with toxic antibiotics are not common on rabbit farms, but the consequences are severe and feed manufacturers and rabbit breeders must therefore remain vigilant in this respect.

Funding: This research did not receive any specific grant from funding agencies in the public, commercial, or not-for-profit sectors.

Acknowledgements: Catherine R. Martin assisted us with the English language editing. Anonymous referees contributed to improving the manuscript. Our recognition goes to all of them. This paper is in memory of Dominique Licois (1948-2019).

Conflicts of Interest: The authors declare no conflict of interest.

REFERENCES

- Agnoletti F. 2012. Update on rabbit enteric diseases: despite improved diagnostic capacity, where does control and prevention stand? In *Proc.: 10th World Rabbit Congress, September 3-6, 2012, Sharm El-Sheikh, Egypt*, 1113-1127. Available in: <http://world-rabbit-science.com/WRSA-Proceedings/Congress-2012-Egypt/Papers/07-Pathology/PO0-Agnoletti.pdf> Accessed December 2021.
- Agnoletti F., Ferro T., Guolo A., Marcon B., Cocchi M., Drigo I., Mazzolini E., Bano L. 2009. A survey of *Clostridium* spiroforme antimicrobial susceptibility in rabbit breeding. *Vet. Microbiol.* 136, 188-191. <https://doi.org/10.1016/j.vetmic.2008.10.020>
- Carman R.J., Borriello S.P. 1984. Infectious nature of *Clostridium* spiroforme-mediated rabbit enterotoxaemia. *Vet. Microbiol.* 9, 497-502. [https://doi.org/10.1016/0378-1135\(84\)90070-1](https://doi.org/10.1016/0378-1135(84)90070-1)
- European Food Safety Authority (EFSA), 2021. Assessment of animal diseases caused by bacteria resistant to antimicrobials: rabbits. *EFSA Journal*, 19, 6999. <https://doi.org/10.2903/j.efsa.2021.6999>
- Fesce A., Ceccarelli A., Fesce E., Balsari A. 1977. Ecophylaxis: preventive treatment with gentamicin of rabbit lincomycin-associated diarrhea. *Folia Vet. Lat.*, 7: 225-242.
- Fisher P., Graham J. 2018. Rabbits. Ch 10. In: *Carpenter J.W. (ed.), Exotic Animal Formulary, 5th ed., Elsevier, St. Louis MO, USA*, pp 494-531. <https://doi.org/10.1016/B978-0-323-44450-7.00010-2>
- Glenn Songer J., Uzal F.A. 2016. Diseases Produced by *Clostridium* spiroforme. In: *Uzal F.A., Glenn Songer J., Prescott J.F., Popoff M.R. (eds). Clostridial diseases of animals. Wiley Blackwell, Ames, IA, USA*, pp. 221-227.
- Gray J. E., Lewis C. 1966. Enigma of Antibiotic-Induced Diarrhea in the Laboratory Rabbit. *Toxicol. Appl Pharmacol.* 8: 342.
- Harcourt-Brown F. 2002. Therapeutics. Ch 4. In: *Textbook of rabbit medicine. Butterworth-Heinemann, Oxford, UK*, pp 94-120. <https://doi.org/10.1016/B978-075064002-2.50007-2>
- Harkness J.E., Turner P.V., VandeWoude S., Wheler C.L. 2010. Harkness and Wagner's Biology and Medicine of Rabbits and Rodents, 5th ed. *Wiley-Blackwell: Ames, IA, USA*, p. 298.
- Lafargue-Hauret P., Jarrin D., Ricca V., Rouillere H. 1994. Toxicité de l'amoxicilline chez le lapin. In *Proc.: 6^{mes} Journées de la Recherche Cunicole. La Rochelle, France, 6-7 December, 81-84.*
- Le Guennec J., Quéré C., Le Normand B. 2007. Isolements, cultures et antibiogrammes sur *Clostridium* spiroforme issus d'élevages de lapin. In *Proc.: 12^{mes} Journées de la Recherche Cunicole, Le Mans, France, 27-28 November, 227-229.*
- Lebas F. 2020. Biology of the rabbit. Available at: <http://www.cuniculture.info/Docs/Biologie/Biologie-English/Biology-Eng-04.htm#4> Accessed October 2021.
- Licois D. 1996. Risques associés à l'utilisation des antibiotiques chez le lapin: une mini revue. *World Rabbit Sci.*, 4: 63-68. <https://doi.org/10.4995/wrs.1996.272>
- Licois D. 2009. Pathologie d'origine bactérienne et parasitaire chez le lapin: Aports de la dernière décennie. In *Proc.: 13^{mes} Journées de la Recherche cunicole, Le Mans, France, 17-18 November, 175-186.*
- Marlier D., Dewrée R., Lassence C., Licois D., Mainil J., Coudert P., Meulemans L., Ducatelle R., Vindevoel H. 2006. Infectious agents associated with epizootic rabbit enteropathy: Isolation and attempts to reproduce the syndrome. *Vet. J.*, 172: 493-500. <https://doi.org/10.1016/j.tvjl.2005.07.011>
- Morisse J.P., Le Gall G., Boilletot E., Maurice R. 1989. Intoxication alimentaire chez le lapin par des résidus d'antibiotiques. *Cuniculture*, 90, 288.
- Oglesbee B.L., Lord B. 2020. Gastrointestinal diseases. Ch 14. In: *Quesenberry K. E., Orcutt C.J., Mans C. Carpenter J.W. (eds.), Ferrets, Rabbits, and Rodents. Clinical Medicine and surgery, 4th ed., Elsevier, St. Louis, MO, USA*, pp 174-187. <https://doi.org/10.1016/B978-0-323-48435-0.00014-9>
- Peeters J.E., Pohl P., Charlier G. 1984. Infectious agents associated with diarrhea in commercial rabbits: A field study. *Ann. Rech. Vet.* 15: 24-29.
- Peeters J.E., Geeroms R., Carman R.J., Wilkins T.D. 1986. Significance of *Clostridium* spiroforme in the enteritis-complex of commercial rabbits. *Vet. Microbiol.*, 12: 25-31. [https://doi.org/10.1016/0378-1135\(86\)90038-6](https://doi.org/10.1016/0378-1135(86)90038-6)
- Rosell J.M., de la Fuente L.F. 2016. Causes of mortality in breeding rabbits. *Prev. Vet. Med.*, 127: 56-63. <https://doi.org/10.1016/j.prevetmed.2016.03.014>
- Rosell J.M., de la Fuente L.F. 2018. Mastitis on rabbit farms: prevalence and risk factors. *Animals*, 8: 98. <https://doi.org/10.3390/ani8060098>
- Rosell J.M., de la Fuente L.F., Badiola J.I., Fernández de Luco D., Casal J., Saco M. 2009. Study of urgent visits to commercial rabbit farms during 1997-2007. *World Rabbit Sci.* 17: 127-136. <https://doi.org/10.4995/wrs.2009.652>
- Solans L., Arnal J.L., Sanz C., Benito A., Chacón G., Alzaguren O., Fernández A.B. 2019. Rabbit Enteropathies on Commercial Farms in the Iberian Peninsula: Etiological Agents Identified in 2018–2019. *Animals*, 9, 1142-1152. <https://doi.org/10.3390/ani9121142>
- Thilsted J.P., Newton W.M., Crandell R.A., Bevil R.F. 1981. Fatal diarrhea in rabbits resulting from the feeding of antibiotic-contaminated feed. *J. Am. Vet. Med. Ass.* 179: 360-361.
- Whitney J.C. 1974. Treatment of enteric disease in the rabbit. *Vet Rec.*, 95: 533. <https://doi.org/10.1136/vr.95.23.533-a>