

OUTBREAKS OF MYXOMATOSIS IN EGYPTIAN DOMESTIC RABBIT FARMS

SALEM H.M.*, MORSY E.A.*, HASSANEN E.I.†, SHEHATA A.A.‡

*Department of Poultry diseases, Faculty of Veterinary Medicine, Cairo University, P.O. Box 12211, GIZA, Egypt.

†Department of Pathology, Faculty of Veterinary Medicine, Cairo University, P.O. Box 12211, GIZA, Egypt.

‡Avian and Rabbit Diseases Department, Faculty of Veterinary Medicine, University of Sadat City, SADAT CITY, Egypt.

Abstract: Myxomatosis is an endemic infectious, severe and often fatal disease of rabbit caused by myxoma virus. In the present study, myxomatosis outbreaks were reported in 7 domestic rabbit farms in Egypt. Rabbits showed oedema of the eyelids, facial oedema and blepharoconjunctivitis. The morbidity and lethality rates were 18-100% and 20-80%, respectively. The myxomatosis diagnosis was based on histopathology, virus isolation on rabbit kidney cell line (RK-13), polymerase chain reaction (PCR) and sequence analysis. Histopathological examination revealed the presence of epidermal hyperplasia, dermal necrosis and intracytoplasmic eosinophilic inclusion bodies. The virus was isolated on RK-13 cells and induced cytopathic effect. Using PCR, a band of 471 base pair corresponding to the M071L gene was amplified from extracted DNA. Sequence alignment of four out of the 7 isolates revealed that these isolates were 98-99% identical to European and Australian rabbit myxoma reference viruses. In conclusion, rabbit myxomatosis outbreaks and virus isolation procedures are reported herein for the first time in Egypt. Preventive policies against disease circulation should be adopted by the national authorities.

Key Words: rabbit myxomatosis, isolation, PCR, Egypt.

INTRODUCTION

Rabbit myxomatosis is a worldwide distributed enzootic disease of wild and domestic rabbits. The disease is caused by rabbit myxoma virus (MYXV), which belongs to family *Poxviridae*; subfamily *Chordopoxvirinae*; genus *Leporipoxvirus*. The genus *Leporipoxvirus* includes four viruses, namely MYXV, hare fibroma virus, squirrel fibroma virus and Shope fibroma virus. The 4 viruses are genetically and antigenically related (Cameron *et al.*, 1999, Willer *et al.*, 1999). Like other poxviruses, MYXV has a classic large brick-shaped virion, enveloped, double stranded linear DNA genome of 163 kilobases (kb) which encode 171 unique genes and are flanked by terminal inverted repeats. The MYXV replicates in the cytoplasm of the infected cells, where a wide range of immunomodulatory proteins that play a role in viral pathogenesis immune-evasion are elaborated (Kerr and McFadden 2002, Moss *et al.*, 2001).

Two clinical forms of rabbit myxomatosis have been described; a classic form (myxomatosis, nodular or typical form) and an atypical form (amyxomatous form). The classical form is often fatal and characterised by skin pseudotumours (myxomas) and swelling of the muzzle, anogenital region and blepharoconjunctivitis, while the atypical or amyxomatous form shows variable degrees of severity (Moss *et al.*, 2001, Bertagnoli and Marchandeu, 2015). The high mortality rates (usually 10-14 d post infection) are due to multi-organ dysfunction, progressive conjunctivitis and severe immunosuppression in which the disease is accompanied by secondary bacterial infection (Fenner, 2000). The virus is passively transmitted (mechanical) by biting arthropods such as mosquitoes and fleas (Grodhaus *et al.*, 1963, Brugman *et al.*, 2015, Dalton *et al.*, 2015).

Correspondence: Awad A Shehata, dr_awadali_1@yahoo.com. Received August 2018 - Accepted March 2019.
<https://doi.org/10.4995/wrs.2019.10585>

Nowadays, MYXV is endemic in North and South America, Europe and Australia. However, in Egypt there are no available data on the presence of the disease. This study reports rabbit myxomatosis outbreaks for the first time in the country.

MATERIALS AND METHODS

History of rabbits and sampling

Seven outbreaks of rabbit myxomatosis were recorded in 5 Governorates (Qalyoubia, Behira, Alexandria, Shraqia and Giza) in Egypt between autumn 2016 and spring 2017. Clinical disease was observed in rabbits 70-90 d old, with high mortality rates in some farms. The background information on these farms including the age, breed and signs of the disease, morbidity and mortality rates, and previous vaccination was collected during autumn 2016 and spring 2017 (Table 1), this period is the most favourable for mosquitoes spreading in Egypt. Freshly dead animals were examined for post-mortem lesions and samples (skin lesions, parenchymatous organs) were collected from all farms for histopathology and virus isolation. Tissue specimens from skin and different organs were fixed in 10% neutral buffer formalin (pH 7.0) to be used for histopathological examination.

Histopathological study

Tissue specimens from skin and different organs (liver, spleen, heart & caecal tonsil) were taken from rabbits and fixed in 10% neutral buffer formalin (pH 7.0). The specimens were trimmed and processed by conventional method using ascending grade of alcohol. Cutting at 4.5 µm was performed to obtain paraffin sections stained by haematoxylin and eosin (H&E) for histopathological examinations.

Virus isolation

Virus isolation was performed on rabbit kidney (RK-13) monolayer cells grown in cell growth medium (CGM) containing Eagle's minimum essential medium (MEM, Gibco Invitrogen Corporation) and supplemented with 100 UI/mL penicillin, 60 µg/mL streptomycin, 50 µg/mL gentamicin and 10% foetal calf serum (FCS, Gibco Invitrogen Corporation). Samples (samples of 5 rabbits of skin lesions, parenchymatous organs/outbreak) were filtered using 0.45 µm bacteriological filters, inoculated onto the confluent RK-13 monolayer in 25 cm² flasks (NUNC™, Denmark) and incubated 1 h at 37°C for adsorption. Subsequently, the inoculums were removed and the infection media (MEM, 2% FCS) was added. Cells were incubated at 37°C in an atmosphere of 5% CO₂ for 7 d and examined daily for the presence of cytopathic effect (CPE). In the absence of CPE, a second blind passage was performed. For identification of the isolated viruses, polymerase chain reaction (PCR) was done on harvested cell culture supernatants (2nd and 4th passages) as described below.

Table 1: The evolution of outbreaks.

Sample no.	Location	Breed	Age/day	Morbidity%	Lethality%	season	Vaccination schedule
1	Qalyoubia	Californian and New-Zealand	70	100	80	Spring 2017	<i>Pasteurella</i> , RHDV, Rota, <i>E. coli</i> and <i>Clostridium</i> sp.
2	Qalyoubia	New-Zealand	75	50	40	Spring 2017	<i>Pasteurella</i> , RHDV
3	Behira	New-Zealand	80	20	20	Spring 2017	<i>Pasteurella</i> , RHDV
4	Alexandria	Chinchilla and New-Zealand	86	45	35	Autumn 2016	<i>Pasteurella</i> , RHDV
5	Sharqia	New-Zealand	90	22	28	Autumn 2016	<i>Pasteurella</i> , RHDV
6	Giza	Flemish and Baladi	90	18	30	Autumn 2016	<i>Pasteurella</i> , RHDV
7	Giza	Bouscat and New-Zealand	90	23	35	Autumn 2016	<i>Pasteurella</i> , RHDV

PCR

DNA was extracted from harvested samples (5 pooled samples from skin lesions, parenchymatous organs/outbreak) using a DNA extraction kit (QIAGEN GmbH, Hilden, Germany) according to the manufacturer's instructions. PCR was performed to amplify a 471 base pair (bp) of M071L gene using M071-F (5'-ACC-CGC-CAA-GAA-CCA-CAG-TAG-T-3': location 67 229 nt-67 250 nt) and M071-R (5'-TAA-CGC-GAG-GAA-TAT-CCT-GTA-CCA-3': location 67 700 nt-67,677 nt) as forward and reverse primers (Metabion International AG, Planegg, Germany), respectively (Cavadini *et al.*, 2010). Briefly, 4 μ L of DNA of field samples and negative controls were added to 25 μ L of 2 \times master mix, 1 μ L of each primer (20 pmol/ μ L), 1 μ L DNA polymerase (Bioline, Luckenwalde Germany) and 18 μ L of distilled water. The cyclor setting was 95°C/3 min; 40 \times (95°C/30 s, 55°C/30 s, 72°C/50 s) and 72°C/5 min. The PCR product was analysed on an agarose gel (1.5%) by electrophoresis and visualised using a UV transilluminator.

Sequencing and sequence analysis

Nucleotide sequencing was done on randomly selected four out of seven isolates, respectively designated MYX ME/4, MYX ME/5, MYX ME/6 and MYX ME/7 using the Rhodamine Dye-Terminator Cycle Sequencing Kit (Big Dye Terminator v1.1; Applied Biosystems), followed by analysis in an ABI PRISM TM310 Genetic Analyzer (Applied Biosystems). Sequences were edited using EditSeq (DNASTAR Inc., Madison, WI, USA). For generation of phylogenetic trees, additional rabbit MYXV sequences in GenBank were retrieved. The maximum likelihood method based on the Tamura-Nei model was used for evolutionary history and the tree was presented with the highest log likelihood. Sequence alignments and phylogenetic tree were performed using MEGA5.

RESULTS

History, clinical signs and post-mortem lesions

Clinical disease was observed in 6 different rabbit breeds, namely Californian, New Zealand, Chinchilla, Flemish, Baladi and Bouscat at 70-90 d of age. Facial lesions were evident in rabbits from all investigated farms. The most prominent lesions observed were oedema, eyelid erythema, facial myxomas and blepharoconjunctivitis and, in some



Figure 1: Clinical picture of rabbit myxomatosis. Rabbits showing oedematous swelling of upper eye lid (A), conjunctivitis with lacrimation (B) and myxomas extended from upper lip, localized pseudo tumour over growth covered by crusts (C).

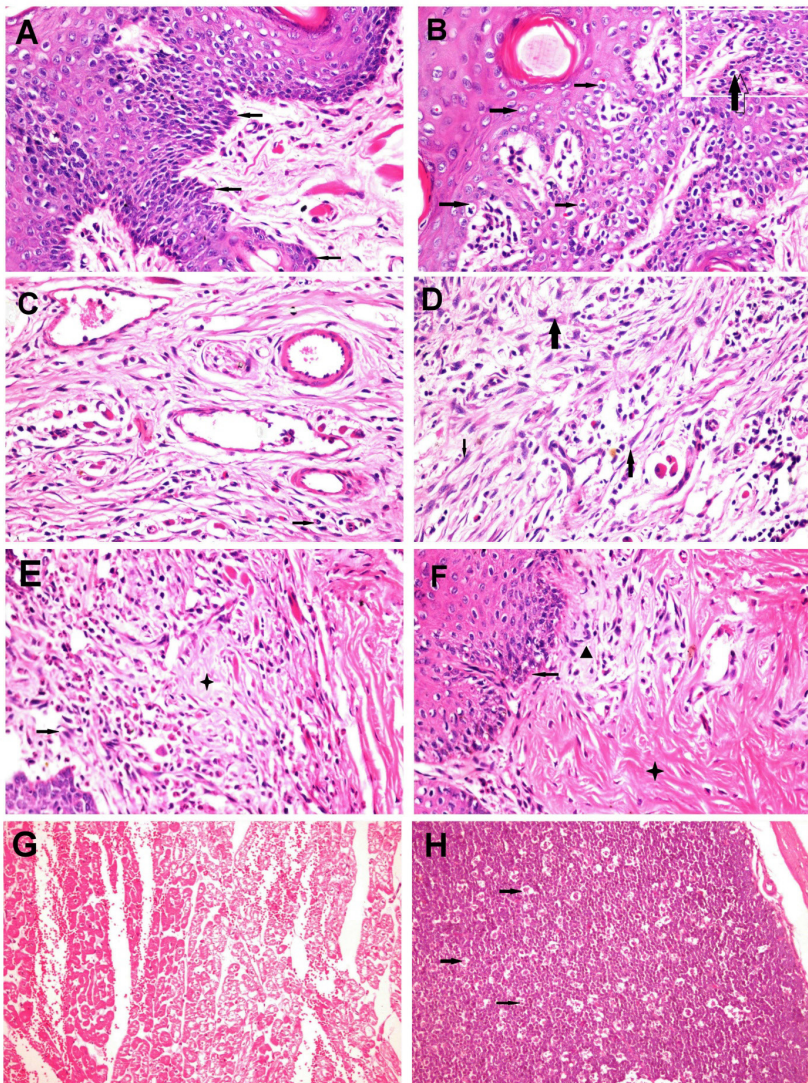


Figure 2: Histopathologic examination of skin and visceral organs of rabbits suffered from myxomatosis: (A) Epidermal hyperplasia (arrows) with vacuolar degeneration in spinous cell layer (H&E 200×). (B) Epidermal hyperplasia and vacuolar degeneration with presence of intracytoplasmic eosinophilic inclusion bodies (arrows) (H&E 200×). (C) Fibroblast proliferation with mild mononuclear inflammatory cells (arrow) infiltration in the dermis (H&E 400×). (D) Stellate, spindle cells (arrows) in abundant mucinous matrix in the dermis with moderate mononuclear cells (star) infiltrations (H&E 400×). (E) Pleomorphic cells (arrow) in abundant myxoedematous materials (star) with fibroblast cells in the dermis in addition to moderate haemorrhage (H&E 400×). (F) Epidermal hyperplasia (arrow), dermal myxomatosis (arrow head) with hyalinosis (star) of the dermal connective tissue (H&E 200×). (G) Heart showing degeneration and necrosis of cardiac muscle with extensive haemorrhage in between (H&E 200×). (H) Cecal tonsil showing destruction of lymphocytes in lymphoid follicles and lymphoid depletion with presence of tangible body macrophages (arrows) (H&E 200×).

cases, the cutaneous lesions extended from the skin covering the nose. The skin of most cases presented localised overgrowth or pseudo-tumour mass covered with crusts. Ocular and nasal discharges were also observed in some cases (Figure 1). Rabbits also showed depression, anorexia and severe emaciation. Post-mortem lesions revealed congestion and haemorrhages in the internal organs. Morbidity rates ranged between 18-100%, while the lethality rates varied from 20-80% (Table 1) during the observation period (4 wk after emergence of outbreaks). Stamping-out policy was not adopted, and only symptomatic treatment was applied to control the disease. All the examined farms had a history of vaccination against Pasteurellosis and rabbit haemorrhagic disease (RHD). Rabbits from farm No. 1 were additionally vaccinated against rotavirus, colibacillosis and clostridiosis. Investigation of the farms revealed that all were heavily infested with mosquitoes.

Histopathological examinations

The most prominent microscopic lesion observed in the skin was epidermal hyperplasia, characterised by hyperkeratosis and acanthosis increasing the epidermal layer thickness (Figure 2A). Epidermal cellular swelling and vacuolar degeneration was noted in all sections, along with presence of intracytoplasmic eosinophilic inclusions in the degenerated cells (Figure 2B). The epidermis and dermis were infiltrated with mononuclear inflammatory cells, mainly lymphocytes and plasma cells, as well as a few neutrophils present in addition to proliferation of fibroblast cells in the dermal layer (Figure 2C). A particular feature was the presence of stellate, spindle cells with or without intracytoplasmic eosinophilic bodies (ICIB) in abundant mucinous matrix in the dermis (Figure 2D, 2E). Dermal necrosis with hyalinosclerosis as well as haemorrhage was also recorded in most sections (Figure 2F). Hair follicles showed destruction in its epithelial lining, which desquamated into the follicular cavity and mixed with inflammatory cells. Most of the hair follicles dilated and blocked by keratin in addition to pre follicular sclerosis and leucocytic cell infiltration, while others atrophied with destructed epithelial lining. Muscular layer showed Zenkers necrosis in addition to oedema, with severe infiltration of inflammatory cells. Visceral lesions were occasionally observed; necrosis, oedema and haemorrhage were detected in lymphoid organs, kidneys, liver, and heart (Figure 2G). There was lymphoid depletion in the spleen, caecal tonsils and lymph nodes, with destruction of mature lymphocytes (Figure 2H). Eosinophilic ICIB were also observed in the degenerated epithelial cells of the visceral organs.

Virus isolation

At the 2nd passage, infected RK-13 cells with isolates No. 1, 2, 3, 4, 5 and 7 showed CPE. However, isolate No. 6 induced CPE at the 3rd passage. The CPE started with rounding and detachment of cells from the monolayer. Later, all cells were affected, and the cell monolayer detached completely (Figure 3). The presence of rabbit MYXV was confirmed using PCR performed on second and fourth passages for detection of a 471 bp corresponding to the M071L gene (data not shown).

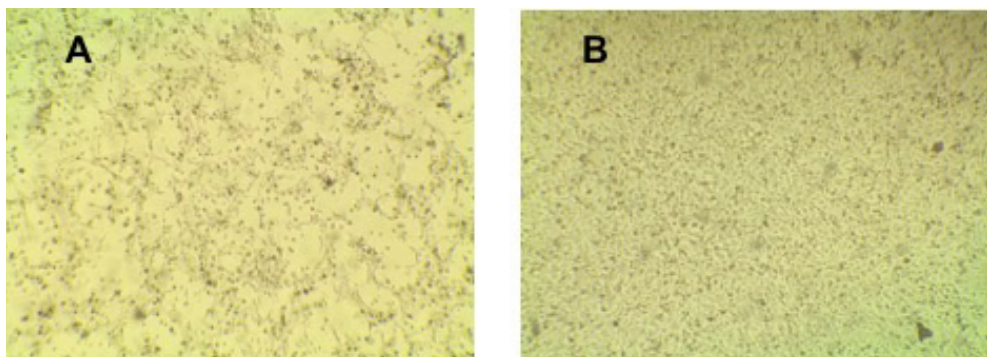


Figure 3: Isolation of rabbit myxoma virus on RK-13 cells. A) RK-13 cells infected with rabbit MYXV field isolate-4 showing focal rounding and detachment of cells at 4 dpi. B) Monolayer culture of RK-13 cells.




Figure 4: Phylogenetic analysis of the isolated rabbit myxoma viruses ME-MYX4, ME-MYX5, ME-MYX6 and ME-MYX7. The strains isolated in the current study are indicated by a red circle. The reliability of the phylogenetic tree was evaluated by bootstrap analysis of 1000 replicates.

PCR and sequence analysis

PCR employed on the field samples (samples of 5 rabbits/outbreak) confirmed that all samples were positive for rabbit MYXV. All samples showed a band of 471 bp corresponding to the M071L gene. The MYX ME/4, MYX ME/5, MYX ME/6 and MYX ME/7 clustered with European and Australian reference strains (Figure 4) and exhibited a high identity 98-100% with Cornwall/4-54/1, Lausanne, Nottingham/4-55/, Perthshire-2524, Uriarra and Yorkshire/127, SWH 8/2/93, KM13, Bendigo, BRK, Yorkshire KY548813 and 99% with Glenfield. However, the 4 viruses exhibited relatively lower homology with Borghi (93-94%) and California/San Francisco (91-92%). The currently isolated viruses are 86-87% identical with Rabbit fibroma virus. The MYX viruses are currently clustered with European and Australian MYX viruses. The sequences were submitted to the GenBank under accession numbers (MH107056-9).

DISCUSSION

Myxomatosis continued to be endemic in several countries and is still a relevant threat for rabbit industries (Kerr, 2012; Dalton *et al.*, 2015). However, to date there is no record on the prevalence or distribution of the disease in Egypt. In the present study, seven outbreaks of myxomatosis were reported in Egypt for the first time. Clinical disease was observed in different rabbit breeds at 70-90 d of age, with variable lethality rates (20-80%). Several factors cause variation in the mortality rate, such as farm hygiene, the host immunity, age of infected rabbits, control of arthropods, biosecurity measures and the MYXV virulence. Secondary bacterial infections with *Pasteurella* spp. and *Bordetella* spp. of the conjunctivae, upper respiratory tract, and lungs are typical in rabbits that survive longer than 10-14 d after infection and could be the major cause of death in rabbits infected with sub-acute strains of MYXV (Best *et al.*, 2000; Silvers *et al.*, 2006; OIE, 2017). In our study, symptomatic treatment was adopted to control the disease using immune stimulant, antibiotics after sensitivity testing and anti-inflammatory drugs.

In our study, histopathological examination revealed the presence of severe ulcerative, necrotising dermatitis, ICIB in the degenerated cells, and infiltration with mononuclear inflammatory cells which are pathognomonic for MYXV. However, microscopic lesions might vary according to the virulence of strains and breeds (Best *et al.*, 2000). The origin of the emerged myxomatosis outbreaks in Egypt is still unclear.

Sequence analysis of the amplified region of 400 bp of four selected viruses (MYX ME/4, MYX ME/5, MYX ME/6 and MYX ME/7) revealed 98-100% identity with reference rabbit myxoma viruses. The percentages of homology are relative only to the short sequence amplified and sequenced and not to the whole genome. Considering the large genomic size and the high number of MYXV proteins expressed, the level of identity with regard to the mentioned strains could be indeed much more variable and different. Interestingly, it seems that the 4 detected strains belong to 2 different clusters, indicating that the outbreaks might be not originated from a single source, but different introduction could be claimed. Further study is urgently needed to understand the molecular epidemiology of the disease in Egypt. The introduction of the virus into Egyptian rabbit farms might be through imported rabbits, further investigations are required to determine the exact origin of the virus. Hence, vaccination might be a successful way to prevent myxomatosis in rabbits (Calvete *et al.*, 2004; Ferreira *et al.*, 2009), and a vaccination scheme should be adopted by the rabbit producers, timely informed by the national authority. In addition, other measures such as control of biting insects, good hygienic practices and quarantine of introduced rabbits should be taken into consideration.

REFERENCES

- Bertagnoli S., Marchandeuau S. 2015. Myxomatosis. *Rev. Sci. Tech.*, 34:549-556. <https://doi.org/10.20506/rst.34.2.2378>
- Best S.M., Collins S.V., Kerr P.J. 2000. Coevolution of host and virus: cellular localization of virus in myxoma virus infection of resistant and susceptible European rabbits. *Virology*, 277: 76-91. <https://doi.org/10.1006/viro.2000.0505>
- Brugman V.A., Hernández-Triana L.M., Prosser S.W., Weland C., Westcott D.G., Fooks A.R., Johnson N. 2015. Molecular species identification, host preference and detection of myxoma virus in the *Anopheles maculipennis* complex (Diptera: Culicidae) in southern England, UK. *Parasit Vectors.*, 8: 421. <https://doi.org/10.1186/s13071-015-1034-8>
- Calvete C., Estrada R., Lucientes J., Osacar J., Villafuerte R. 2004. Effects of vaccination against viral haemorrhagic disease (VHD) and myxomatosis on long-term mortality rates of European wild rabbits. *Vet. Rec.*, 155: 388-392. <https://doi.org/10.1136/vr.155.13.388>
- Cameron C., Hota-Mitchell S., Chen L., Barrett J., Cao J.X., Macaulay C., Willer D., Evans D., McFadden G. 1999. The complete DNA sequence of myxoma virus. *Virology*, 264: 298-318. <https://doi.org/10.1006/viro.1999.0001>
- Dalton K.P., Nicieza I., de Llano D., Gullón J., Inza M., Petralanda M., Arroita Z., Parra F. 2015. Vaccine breaks: Outbreaks of myxomatosis on Spanish commercial rabbit farms. *Vet. Microbiol.* 178: 208-216. <https://doi.org/10.1016/j.vetmic.2015.05.008>
- Fenner F. 2000. Adventures with poxviruses of vertebrates. *FEMS Microbiol. Rev.*, 24:123-133. <https://doi.org/10.1111/j.1574-6976.2000.tb00536.x>
- Ferreira, C., Ramírez, E., Castro, F., Ferreras, P., Alves, P.C., Redpath, S., Villafuerte, R. 2009. Field experimental vaccination campaigns against myxomatosis and their effectiveness in the wild. *Vaccine*, 27: 6998-7002. <https://doi.org/10.1016/j.vaccine.2009.09.075>
- Grodhaus G., Regnery D.C., Marshall I.D. 1963. Studies in the epidemiology of myxomatosis in California. II. The experimental transmission of myxomatosis between brush rabbits (*Sylvilagus bachmani*) by several species of mosquitoes. *Am. J. Hyg.*, 77: 205-212. <https://doi.org/10.1093/oxfordjournals.aje.a120311>
- Kerr P., McFadden G. 2002. Immune responses to myxoma virus. *Viral Immunol.*, 15: 229-246. <https://doi.org/10.1089/08828240260066198>
- Kerr P.J. 2012. Myxomatosis in Australia and Europe: a model for emerging infectious diseases. *Antiviral Res.*, 93: 387-415. <https://doi.org/10.1016/j.antiviral.2012.01.009>
- Moss B. 2001. *Poxviridae: The viruses and their replication*. In: Fields B.N., Howley M.D., Griffin Ph.D., Lamb Ph.D., Martin M.D., Roizman B., Strauss M.D., Knipe Ph. D. (Eds.), *Fields' virology*, 4th ed., Lippincott Williams & Wilkins, Philadelphia, PA, USA. pp. 2849-2883.
- OIE. 2107. Manual of Diagnostic tests and vaccines for terrestrial animals. Chapter 2.6.1. Myxomatosis (NB: Version adopted in May 2014).
- Silvers L., Inglis B., Labudovic A., Janssens P.A., van Leeuwen B.H., Kerr P.J. 2006. Virulence and pathogenesis of the MSW and MSD strains of Californian myxoma virus in European rabbits with genetic resistance to myxomatosis compared to rabbits with no genetic resistance. *Virology*, 348: 72-83. <https://doi.org/10.1016/j.virol.2005.12.007>
- Willer D.O., McFadden G., Evans D.H. 1999. The complete genome sequence of Shope (rabbit) fibroma virus. *Virology*, 264: 319-343. <https://doi.org/10.1006/viro.1999.0002>