

Basic Science

ICR in human cadaveric specimens: An essential parameter to consider in a new lumbar disc prosthesis design



Amparo Vanaclocha-Saiz^{1,*}, Carlos M. Atienza^{2,3}, Vicente Vanaclocha⁴, Vicente Belloch⁵, Juan Manuel Santabarbara⁵, Pablo Jordá-Gómez⁶, Leyre Vanaclocha⁷

¹Escuela de Doctorado, Valencia, Spain

²Instituto de Biomecánica (IBV) Universitat Politècnica de Valencia, Valencia, Spain

³Instituto de Biomecánica de Valencia-CIBER BBN, Grupo de Tecnología Sanitaria (GTS-IBV), Valencia, Spain

⁴University of Valencia, Valencia, Spain

⁵ASCIREs CAMPANAR, Valencia, Spain

⁶Hospital Politècnic i Universitari La Fe, Valencia, Spain

⁷University College London, London United Kingdom

ARTICLE INFO

Keywords:

Lumbar disc prosthesis
Chronic low back pain
ICR
Disc degeneration

ABSTRACT

Study design: Biomechanical study in cadaveric specimens.

Background: The commercially available lumbar disc prostheses do not reproduce the intact disc's Instantaneous centre of Rotation (ICR), thus inducing an overload on adjacent anatomical structures, promoting secondary degeneration.

Aim: To examine biomechanical testing of cadaveric lumbar spine specimens in order to evaluate and define the ICR of intact lumbar discs.

Material and Methods: Twelve cold preserved fresh human cadaveric lumbosacral spine specimens were subjected to computerized tomography (CT), magnetic resonance imaging (MRI) and biomechanical testing. Kinematic studies were performed to analyse range of movements in order to determine ICR.

Results: Flexoextension and lateral bending tests showed a positive linear correlation between the angle rotated and the displacement of the ICR in different axes.

Discussion: ICR has not been taken into account in any of the available literature regarding lumbar disc prosthesis. Considering our results, neither the actual ball-and-socket nor the withdrawn elastomeric nucleus models fit the biomechanics of the lumbar spine, which could at least in part explain the failure rates of the implants in terms of postoperative failed back syndrome (low back pain). It is reasonable to consider then that an implant should also adapt the equations of the movement of the intact ICR of the joint to the post-surgical ICR.

Conclusions: This is the first cadaveric study on the ICR of the human lumbar spine. We have shown that it is feasible to calculate and consider this parameter in order to design future prosthesis with improved clinical and biomechanical characteristics.

1. BACKGROUND

Chronic lower back pain is one of the most common medical conditions [26]. Degenerative disc disease is an important cause of chronic low back pain, particularly in relatively young people (below 50 years of age) [50]; and zygapophyseal joint osteoarthritis is an important cause of pain in patients older than 50 [51].

Each spinal segment is composed of three mobile elements: one disc anteriorly and two zygapophyseal joints posteriorly. Under normal conditions, the disc supports about 80% of the load transmitted through the

spine [78]. When the intervertebral disc degenerates, it loses its capacity to transmit this load and thus may become a source of low back pain [66].

Lumbar disc arthroplasty was introduced in 1960 [27], although results were not promising until the 1980's [7,36,60,115]. The aim of this surgical procedure is to preserve motion as well as to avoid spinal fusion related complications and side-effects. The first successfully implanted device was the SB Charitè [7,15]. The initial suboptimal results, which occurred due to mechanical failure [7,19,52,101,102], were mitigated by repeatedly improving on the design [60]. Ever since, many other disc

* Corresponding author.

<https://doi.org/10.1016/j.xnsj.2020.100016>

Received 27 April 2020; Received in revised form 29 June 2020; Accepted 15 July 2020

Available online 20 July 2020

2666-5484/© 2020 The Authors. Published by Elsevier Ltd on behalf of North American Spine Society. This is an open access article under the CC BY-NC-ND license (<http://creativecommons.org/licenses/by-nc-nd/4.0/>)

replacements have been introduced, but only a few have stood the test of time.

Traditionally, total disc implant designs have had a ball and socket mechanism [16], which can be constrained, unconstrained or semi-constrained [111]. These lumbar prostheses do not replicate the features of the intact lumbar disc, particularly in what pertains to the Instantaneous centre of rotation (ICR). Hence, although movement is allowed, it is not within the normal ranges. This is particularly true in the case of 3-piece prostheses where the central portion is oftentimes mobile, compared to 2-piece disc replacements [111]. The characteristics often dictate abnormal patterns of translation and rotation, and different ICR distribution than the intact lumbar disc [65]. The most challenging motion is axial rotation, where excess movement has to be controlled by zygapophyseal joints, unless the implant has some ligament-like components that limit the range of movement (ROM) in this direction [85,111].

Studies have shown that the ICR of the intact lumbar disc is not fixed, but moves constantly during the lumbar spinal movements of flexion, extension, rotation and lateral bending [1,3,79].

Currently, the commercially available lumbar disc prostheses do not accommodate to the natural ICR [80,87,111]. This results in an overload of adjacent anatomical structures, particularly the zygapophyseal joints [12,42,79,86,88]. This has been shown to induce accelerated degeneration and with it chronic lower back pain [79].

The aim of this study is to design a new lumbar disc prosthesis based on the anatomy and biomechanics of the lumbar spine, taking into account the physiological ROM (flexion, extension, lateral bending and axial rotation) as well as the ICR. As values in the literature vary depending on the study and the methods used to collect the data (anatomical preparations, Finite Element Analysis of computerized models, X-rays of live patients), we found it essential to obtain firstly our own data from human lumbosacral cadaveric spines. The design and development of new lumbar disc prostheses is based on this data. New prostheses should reproduce the ROM and ICR characteristics of the intact lumbar disc as closely as possible, aiming to reduce the overload of the adjacent anatomical structures and particularly the zygapophyseal joints.

2. MATERIALS AND METHODS

The study was conducted in several steps:

- 1 Specimen selection and preparation
- 2 Anatomical CT studies
- 3 Biomechanical study: ROM retrieval during flexion, extension, lateral bending and axial rotational movements, as well as ICR evaluation during said tests

2.1. Specimen selection and preparation

Twelve lumbo-sacral spine specimens from fresh cadavers, provided by the *Facultat de Medicina i Odontologia, University of Valencia, Spain*, were used. Cadavers were cold preserved since death. Donors' age ranged from 18 to 50 years. Exclusion criteria were previous surgical procedures, trauma, malignancy, infection, demineralization or inflammatory diseases affecting the lumbar and/or sacral spine.

Plain lumbosacral X-ray studies were performed, unless they had been carried out shortly before death. Osteoporosis was ruled out by means of a Dual Energy X-ray Absorptiometry (DEXA) scan of the lumbar and sacral spine areas, counting up from sacrum. In DEXA scan osteoporosis is defined with values of -2.5 or lower, so specimens with these values were discarded. [96] Once specimens were cleared out, all soft tissues except ligaments and intervertebral discs were removed and the spine was sectioned at the T_{12} - L_1 intervertebral disc and at the sacroiliac joints. The ligaments and soft tissues of the facet capsules were left intact to preserve their anatomical and functional integrity. A number was allocated to each specimen to allow identification during the study.

2.2. Morphological baseline mri and ct scan data

After soft tissue removal, CT scan studies were performed with 0.625 mm section images, 1.25 mm collimation, and pitch of 3 (0.75 mm/rotation) from L_1 to the coccyx (GE Healthcare, Milwaukee, WI, USA). The images were 3D reconstructed with an x-y matrix 512×512 in size, an isotropic voxel of $1 \times 1 \times 1$ mm and a slice spacing of 0.5 mm. The CT-scan images were transferred to a computer as Digital Imaging and Communications in Medicine (DICOM). Demineralization was an exclusion criterion, so bone mineral density was assessed. The size and dimensions of each vertebra and the intervertebral disc were measured.

MRI studies were performed with a 1.5 Tesla GE MRI scan (GE Healthcare, Milwaukee, WI, USA), looking for spinal morphology, disc changes as well as for possible zygapophyseal joint osteoarthritis.

Once all morphological studies were completed, specimens were stored at -25°C .

CT and MRI scan images were analysed with the program NETEOUS, developed by our group in the *Instituto de Biomecánica de Valencia (IBV)* in collaboration with INGEOT (University of Oviedo, Asturias, Spain).

Morphological data about geometry, morphometry and dimensions of each lumbar and sacral vertebra, with its individual components and particularly the intervertebral discs, were obtained. We calculated antero-posterior (AP) and lateral (L) vertebral end-plate dimensions as well as the height and angulation of each intervertebral disc.

Disc degeneration was evaluated in all specimens to discard those unsuitable for our studies. with a Pfirrmann grade [73] is a known method of classifying disc degeneration in which grades I and II are considered normal discs, grade III with incipient degeneration but grades IV and V with advanced and severe degeneration respectively. Taking this into consideration Pfirrmann grades I and II were acceptable for all levels but III or higher seen MRI studies was acceptable only in the L_4 - L_5 and L_5 - S_1 levels because this is a common scenario when planning lumbar disc replacement. If present at higher levels the specimens were excluded from the present study. All the selected specimens met the above mentioned degeneration criteria

2.3. Intervertebral discs baseline: icr evaluation

In preparation for the biomechanical studies, specimens were slowly thawed for 4 - 5 h at room temperature. The studies were carried at $22 - 23^\circ\text{C}$, with an environmental humidity of 40%. To prevent unwanted desiccation we sprayed the specimens with 0.9% sodium chloride solution at least every five minutes [46,72,107,111].

We performed kinematic studies with the photogrammetry system KINESCAN/IBV, analysing in each vertebral segment the range of movement in flexion, extension, right and left lateral bending and axial rotation, as well as the ICR. To allow load application we screwed a polyethylene piece with a semi-spherical seat on the superior L_1 end-plate. We potted the coccyx and the sacrum's distal end with acrylic bone cement (SR Triplex Cold, Ivoclar Vivadent AG, FL-9494 Schaan; Liechtenstein) making sure that the L_4 - L_5 disc centre plane remained horizontal.

A second base was fixed at the superior portion of the spine (L_4) and a 450 mm bar was screwed on. At the ends of this bar 10 Kg weights were hung, in such a way that a flexor moment of $\pm 25.5\text{Nm}$, as well as a 0 to 100 N compression was able to be applied. This simulated physiological loading conditions [11,97,118]. The superior portion of the system was free, in order to allow greater mobility. The weight control was carried out manually. (Fig. 1)

The system movement was obtained by the Kinescan IBV photogrammetry system, inserting clusters of passive markers in each vertebral body (Fig. 2). Additionally, three anatomical markers were secured to each vertebra by means of screws (Fig. 1). These markers were used to define a local system of coordinates in the position of reference.

Each test consisted of the repetition of a cyclic series of flexion and extension movements through the progressive application of the load



Fig. 1. Kinematic setup.

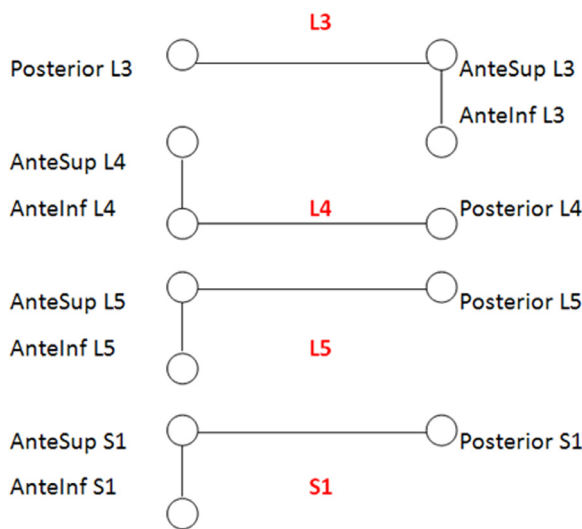


Fig. 2. Marker definition.

on either side of the bar. For each test, 5 cycles were completed. The recording frequency used was 25 frames per second, and the recording time was 1 second.

The measurement system was adjusted to cover $0.7 \times 0.7 \times 0.7$ m³, an active area slightly larger than the volume occupied by each specimen. To improve the accuracy of the measurements a procedure based on beam adjustment (Bundle Adjustment) was used, which corrects the optical distortions and provides accuracy in the order of 0.3 mm in the measurement of the coordinates of the markers.

The accuracy in the measurement of the position variables was calculated using the procedure described by [67]. Taking into account the dimensions of the cluster of markers and their number, the estimated errors corresponding to instantaneous values (individual position measurements) were defined as:

- Displacement measurement error $sRG = \sqrt{2} \cdot 0.3 / \sqrt{9} = 0.14$ mm
- Angle measurement error $sq = \sqrt{2} \cdot 0.3 / \sqrt{J} = 0.004$ rad = 0.25°; where J = moment of inertia of the marker cloud with respect to its centre of gravity

Random errors were reduced using two strategies also previously described by Page et al.: (a) a local adjustment procedure that reduces the instantaneous error by a quarter [69] and (b) the five times repetition of each cycle as well as calculating the average in the geometric domain, in order to obtain the position of the instantaneous rotation axes with an error of a tenth of a millimetre [68].

To obtain the rotation angles of the vertebrae according to the moments applied for each type of test, a vector of a 100 values per second, with a total of 100 values, was exported from each variable that represents the proper rotation of each vertebra. The value of the angles that was taken into account for the analysis will be their average value.

Then, the method described by Page et al. [70] was used to obtain the equations that describe the position of the ICR of each vertebral body, depending on their relative position.

These equations were used for the design of the contact surfaces of the intervertebral disc prosthesis.

The instantaneous axes of rotation of the intervertebral movement in the lumbar spine were then determined, in order to obtain information for the development of an ideal lumbar prosthesis.

3. RESULTS

None of the specimens showed spinal pathologies or signs of osteoporosis, measured by DEXA and confirmed by MRI and CT studies. The specimens had a mean age of 41.06 ± 6.14 SD years (range 31–50 years), a mean body height of 1.73 ± 1.46 SD m (range 1.56–1.79 m), and a mean body weight of 73.08 ± 7.93 SD kg (range 56–87 kg). The mean BMI was 23.25 ± 1.64 SD (range 21.16–27.49).

Tables 1 and 2 contain the specimens' L₄, L₅ and S₁ vertebral body dimensions with their statistical analysis. These data were within normal range and comparable to those available in the literature [5,56,114]. No specimen had any atypical bone morphology or spinal deformity and MRI findings were compatible with normal healthy spines.

Tables 3 and 4 show the results of the rotation angles of the vertebrae according to the moments applied for each type of test. The displayed graphs are standardized, after treatment of the angle values, so that; (a) all coincide in the sign of the slope and (b) all start from the origin of coordinates, in order to compare the values of the vertebrae with each other. For a more detailed representation of the results, it has been preferred to export the values of the variables for later processing in an EXCEL spreadsheet.

Flexion-extension movements at the level of L₃-L₄, L₄-L₅ and L₅-S₁ were analysed.

The obtained data for the three levels are shown in Table 3. In all cases, there was a positive linear correlation between angle rotation and displacement.

The results show that as the lumbar level increases, the angular range decreases. Nevertheless, on all levels the ICR was displaced vertically downwards as the flexoextension movement occurred.

For L₃/L₄ level, the Instantaneous Axis of Rotation (IAR) was found to be centred at the middle of the vertebral body, 2.4 cm below the superior vertebrae, whereas at L₄/L₅ it was found at 5 mm above the centre and 1.5 cm below the superior vertebral body base. The L₅/S₁ IAR was centred approximately at mid-vertebral body, 1.8 cm below the base of the superior vertebral body.

Lateral flexion movements at the level of L₃-L₄, L₄-L₅ and L₅-S₁ were analysed.

The data obtained for the three levels are shown in Table 4. Similar to flexoextension, there was a positive linear correlation between the angle rotated and the displacement.

Table 1
Baseline L₄ - L₅ specimen parameters statistics. All dimensions are provided in millimeters.

	L4 vertebral body height	L4 vertebral body width	L4 vertebral body depth	L4 spinal canal diameter	L4-L5 disc height
N valid	12	12	12	12	12
Mean	25.40	46.35	35.15	29.11	13.47
Standard Deviation	1.23	3.05	2.15	8.65	2.27
Range	4.16	10.36	6.40	24.90	7.42
Min	23.07	40.79	32.02	10.31	8.72
Max	27.23	51.15	38.42	35.21	16.14

Table 2
Baseline L₅ - S₁ specimen parameters statistics. All dimensions are provided in millimeters.

	L5 vertebral body height	L5 vertebral body width	L5 vertebral body depth	L5 spinal canal diameter	L5-S1 disc height
N valid	12	12	12	12	12
Mean	21.40	52.25	34.23	36.00	11.70
Standard Deviation	2.47	4.21	1.99	2.10	2.37
Range	9.32	13.28	6.57	7.27	7.06
Min	16.71	43.19	30.68	31.87	8.81
Max	26.03	56.47	37.25	39.14	15.87

Table 3
Summary of the results of the flexion-extension movement analysis.

	L ₅ -S ₁		L ₄ -L ₅		L ₃ -L ₄	
	Rep 1	Rep 2	Rep 1	Rep 2	Rep 1	Rep 2
Angular range (°)	[-1.5, 4.8]	[-1.5, 4.8]	[-1.5, 2.7]	[-1.1, 3.0]	[-2.1, 1.8]	[-3.4, 2.1]
R adjustment	0.997	0.997	0.999	0.999	0.999	0.996
X_{EIR} range [EXTENSION, FLEXION] (mm)	[-3.7, 4.2]	[-3.1, -3.3]	[7.3, 10.8]	[5.8, 9.3]	[-1.8, -4.1]	[-7.1, -9.9]
Z_{EIR} range [EXTENSION, FLEXION] (mm)	[-22.2, -4.4]	[-23.5, -5.8]	[-10.4, -20.21]	[-9.0, -18.9]	[-29.0, -19.5]	[-25.5, -12.3]
IAR_{neutral} (X, Z) (mm)	(-4.0, -18.0)	(-3.2, -18.8)	(8.5, -14.1)	(6.7, -11.5)	(-2.9, -23.5)	(-8.1, -17.1)

Table 4
Summary of the results of the lateral bending movement analysis.

	L ₅ -S ₁		L ₄ -L ₅		L ₃ -L ₄	
	Rep 1	Rep 2	Rep 1	Rep 2	Rep 1	Rep 2
Angular range (°)	[-1.7, 1.1.1]	[-0.8, 1.8]	[-3.2, 1.1]	[-2.7, 1.8]	[-3.5, 4.8]	[-2.3, 5.4]
R adjustment	0.970	0.971	0.986	0.986	0.9069	0.999
X_{EIR} range [EXT,FLEX] (mm)	[6.8, 9.4]	[1.8, 3.6]	[1.8, 9.0]	[-0.1, 6.6]	[11.5, 6.9]	[4.3, 0.6]
Z_{EIR} range [EXT,FLEX] (mm)	[-5.0, -13.3]	[3.9, -3.6]	[-0.4, -6.4]	[-0.9, -6.6]	[1.1, 20.6]	[11.3, 29.1]
IAR_{neutral} (X, Z) (mm)	(8.4, -10.3)	(2.3, 1.9)	(4.4, -4.8)	(7.1, -4.8)	(9.5, 9.6)	(3.4, 16.6)

The lateral bending results showed that as the lumbar level increased, so did the angular range. Nevertheless, on all levels the ICR was moved vertically 1 cm up and down during lateral loading. The repetitions showed similar results with respect to the range of movement and IAR. Nevertheless, there was a slight position lag, suggesting the occurrence of permanent deformation during the previous test.

With respect to the IAR, at L₃/L₄ level it occupied a horizontal position approximately at the centre of the vertebral body, whereas at L₄/L₅ it was slightly deviated towards the left of the origin and a few below the base, and at L₅/S₁ level it occupied a fixed position 1 cm below the superior vertebral body and 8 mm off-centred towards the left side.

4. DISCUSSION

Degenerative disc disease is a common cause of chronic low back pain [14], and its gold standard treatment is lumbar fusion [47,49,55], which is frequently associated with long term pain recurrence [48,112]. The problem has always been the degeneration of the anatomical structures adjacent to the spinal fusion [39,49] mainly the zygapophyseal joints and the disc. Total lumbar disc replacement was introduced more than 40 years ago [15] attempting to preserve motion. The idea behind it was that motion preservation should mean a smaller risk of adjacent level degeneration. . Incidence of adjacent level disease after lumbar fusion has been reported to range from 11.7% [116], 12.1% [4] to 13.4% [62] at two years to 19.3% ten years follow-up [64]. This has been

proven true in many studies [38,43,77,117]. Over the years, the materials used to manufacture them have been improved to reduce complications like subsidence [55,61,75], particulate debris coming from the disc replacement components [101,103,106,110] and vertebral body fractures related with keel-like designs [91,99].

Although there has been a significant improvement, persistent low back pain after a lumbar disc replacement is still fairly frequent [41,63]. The sources of this pain can vary, but one recurring issue is the degeneration of the zygapophyseal joints of the index and adjacent levels [46,71,95]. Several studies have analysed the direct relationship between the height or movement of the disc replacement and the progression of the facet joint degeneration [25,46,80,83].

Some research groups have reported that currently marketed artificial lumbar disc replacements allow movement above the physiological ranges and do not mimic the ICR of the intact lumbar disc [1,88]. Hence, it is key to investigate how to improve physiological ranges of prostheses while reducing the incidence and severity of adjacent level degeneration, and with it the recurrence of lower back pain.

Most of the currently designed lumbar disc prosthesis do not restrict axial rotation (Charité, Activ-L, Baguera), so this excess of rotational movement has to be controlled by the zygapophyseal joints. Ligament-based prosthesis (i.e. M6-L™) control this type of movement but their elastomeric nucleus might undergo long-term degeneration and rupture [13,89].

With these considerations in mind, complete lumbar disc prostheses can be categorized into two main groups: those that have an elastomeric nucleus and those inspired in the hip joint ball-and-socket principle. This first group of disc replacements (M6-L™, Spinal Kinetics, Sunnyvale, California, USA; Cadisc-L™, Ranier Technology, Cambridge, UK; Freedom Lumbar Disc™, Axiomed Spine, Cleveland, OH, USA) attempt to reproduce the characteristics of the native intervertebral disc. Their main risk is that in the long term the elastomeric nucleus or the artificial annulus might detach from the metallic endplates [89]. This has already happened in the past with other models, forcing their market removal [20,23] (Acroflex™, Acromed Corporation, Cleveland, OH, USA). Thus, it is not an ideal long term solution, particularly because most of the patients who are operated on are middle-aged so lumbar disc prostheses should last at least 30 to 40 years, since removing and replacing lumbar disc prosthesis is a very dangerous endeavour [9,19,76].

The implants of the second group, inspired in the ball-and-socket principle, are usually composed of three elements: two metallic endplates and a middle piece. This middle piece can either (1) move freely (SB III Charité™, DePuy Spine, Inc., Raynham, MA, USA), (2) move in a semi-constrained form (ProDisc-L™, Synthes Spine, West Chester, NY, USA; Activ L™, Aesculap, Tübingen, Germany; Baguera™, Spineart, Geneva, Switzerland) or (3) do not move at all (Maverick™, Medtronic SofamorDanek, Inc., Memphis, TN, USA). Devices with a mobile core (Charité III™) induce in extension a zygapophyseal joint overload, and thus can accelerate the degeneration of this joint [72]. The lumbar disc prostheses with a fixed central piece (Maverick™) do not overload these joints as much, but their centre of rotation is fixed. Thus, they do not reproduce the native intervertebral disc kinematics, as its ICR moves anteriorly in flexion and posteriorly in extension [21]. This also fosters adjacent anatomical structure overload and degeneration. Facet joint pressure increases in flexion, extension and lateral bending proportionally to the diminution in the radius of the articular surface of the artificial lumbar disc, and decreases in axial rotation [16]. This radius is bigger for SB Charité™ and Prodisc L™, intermediate for Activ L™ and Baguera™ and minimal for Maverick™.

The limitations of the ball-and-socket lumbar disc prostheses currently available in the market are [16]:

- Inability to reproduce normal spinal kinematic and biomechanical features [16,88]. As a result ligaments, muscles and zygapophyseal joints have to stand non-physiological loads [32,53,76,82,92], inducing a 20% complication rate [28] long term need of reoperation in 12.1% [18] and a 13.7% of patients being dissatisfied [94].
- Excessive range of motion, particularly in axial rotation [16]. This must be limited by muscles, ligaments and zygapophyseal joints that support overloads with long term degenerative changes [21,79]. In fact, one of the most common causes of lumbar disc arthroplasty failure is persistent low back pain [108] originating from the facet joints [42,86].
- Dislocation or migration [17,22,32,35,36,52,57,76,81,84,100,102]. This was more common with the non-constrained devices (Charité™) [24], and is favored in case of over-sizing the implant's height [21].
- Wear, tear and deformation [6,31,52,81,101,115]. Both metallic and non-metallic debris induce a local inflammatory reaction with osteolysis [54,101] leading to implant loosening, migration and/or subsidence [103,110]. The amount of debris is bigger in the prostheses with a ultra-high molecular weight polyethylene (UHMWPE) core (Charité™, Prodisc L™, Activ L™, Baguera™) [101,106] and smaller with the metal on metal prosthesis (Maverick™) [8]. Nevertheless, the metallic ions released from the prosthesis can induce systemic reactions, particularly in the case of Cobalt-Chromium-Molybdenum (CoCr₂₈Mo₆ alloy) metal on metal prosthesis [29]. The response has been to cover the articular surfaces with carbon-like diamonds (Baguera™) [30,40], but still needs further improvements.

In our kinematic study, we analysed the biomechanics of the intact lumbar disc with a special emphasis on the ICR. From the results obtained in our study we concluded that the measured vertebral movement during the flexoextension movements corresponds on all cases to a rotation around an axis whose horizontal position is centred at a position of mid-vertebral body. On the other hand, the Instantaneous Axis of Rotation (IAR) is slightly variable due to a small horizontal displacement of the vertebrae as flexion occurs. The IAR is not equal on the three vertebrae, which may be due to small displacements that appear to be different depending on the specimen analysed and may be due to the state of conservation of the specimens.

The ICR distribution has been studied and applied as a diagnostic tool since 1994 [109], who measured the spinal cervical kinematics of healthy and pathological patients that had been subject to cervical injuries, such as whiplash injuries. Many other researchers, such as Abouhossein et al. [1], Inoue et al. [45], Ahmadi et al. [2] and Bifulco et al. [10], have studied the kinematics of the lumbar spinal ICR distribution, but each one designed a different testing method and obtained the results with a different model, so the results are slightly different.

The variations observed between our results and those found in the literature can occur due to multiple factors. For example, our study comprised vertebral bodies with ligamentous structures but without muscles, and this provides a closer situation to the live patient [44]. Meanwhile those based on X-rays of live subjects [3,113] do consider this interaction. Nevertheless, the studies reported in the past with finite element analysis [1], or those based on X-rays of live patients [3,113] provide data with limited reliability as confirmed by [1]. Thus, despite the limitations of being cadaveric, the results in our human lumbar spines represent a more accurate approach to obtaining the ICR distribution of a healthy spine, since the others are theoretical (FEA) or animal. Nevertheless, our model can still be improved, as living muscles can change both situation and values [98,105]. Thus, we can consider our results valid in order to properly design the new prostheses taking into consideration the specimen's ICR obtained from human spine cadaveric specimens under 50 years of age.

Having said that, there is a need of an innovative design of the geometry to ensure a correct position of the instantaneous centers of rotation. Our study helps to establish the specifications to design an improved lumbar disc prosthesis capable of reproducing the movement of vertebrae that would most closely resemble real life.

Regarding the clinical specifications, the implant must minimize the following:

- Current surgical issues such as vascular lesions, hematomas and post-surgical infection rates [19,34,74]
- Probability of neurological damage including radiculopathy, dysesthesia, impotence or retrograde ejaculation [33]
- Mechanical problems such as vertebral body fractures, overloading of the articular facets, end plate penetration, dislocation/migration of the implant or any of its components, wear and mechanical failure of joint components [35,91]
- Degenerative problems including arthrosis, adjacent level degeneration, osteolysis secondary to implant wear [93]

With respect to the biomechanical specifications, based on our study, the implant should meet the following requirements:

- Adapts the equations of the movement of the intact ICR of the joint to the post-surgical ICR [3,88]
- Behaves as a shock absorbing mechanism [58]
- Allows the load absorption within the implant so that adjacent levels do not overload [11]
- Biocompatible [37]
- Low implant wear [104]
- Different sizes to adapt to different patient geometries [59]
- Non-complex geometry in order to be readily manufactured [90]

5. STRENGTHS AND LIMITATIONS

One of the main strengths of this study is that real life was emulated. Many studies have been carried out in order to obtain the ICR distribution, but most were mathematical and theoretical models. Another strength of this study is that, when carrying out the lumbar artificial disc replacement implants design, the ICR was taken into consideration. This results in a better adaptation of the physiological loading patterns and ROM of adjacent levels of a healthy lumbar spine. All of this should reduce the overloading on the zygapophyseal joints of the index and adjacent levels, thus reducing post-operative pain and implant failure.

On the other hand, the specimens did not have the muscular support and soft tissue coverage which live patients would have. Data from live patients should be collected to further refine this design.

6. CONCLUSIONS

ICR has not been taken into account in any of the available literature regarding lumbar disc prosthesis.

In this study we have shown that it is feasible to calculate and consider this parameter in order to design future prosthesis, with improved clinical and biomechanical characteristics.

ACKNOWLEDGEMENTS

We thank Manolo Montagud (sales representative from PRIM SA, official local distributor of Alpha Tech), for his help and assistance in this project.

REFERENCES

- [1] Abouhossein A, Weisse B, Ferguson SJ. Quantifying the centre of rotation pattern in a multi-body model of the lumbar spine. *Comput Methods Biomech Biomed Engin* 2013;16:1362-73. <https://doi.org/10.1080/10255842.2012.671306>.
- [2] Ahmadi A, Maroufi N, Behtash H, Zekavat H, Parnianpour M. Kinematic analysis of dynamic lumbar motion in patients with lumbar segmental instability using digital videofluoroscopy. *Eur Spine J* 2009;18:1677-85. <https://doi.org/10.1007/s00586-009-1147-x>.
- [3] Aiyangar A, Zheng L, Anderst W, Zhang X. Instantaneous centers of rotation for lumbar segmental extension in vivo. *J Biomech* 2017;52:113-21. <https://doi.org/10.1016/j.jbiomech.2016.12.021>.
- [4] Bagheri SR, Alimohammadi E, Zamani Froushani A, Abdi A. Adjacent segment disease after posterior lumbar instrumentation surgery for degenerative disease: incidence and risk factors. *J Orthop Surg (Hong Kong)* 2019;27:2309499019842378. <https://doi.org/10.1177/2309499019842378>.
- [5] Banno T, Togawa D, Arima H, Hasegawa T, Yamato Y, Kobayashi S, Yasuda T, Oe S, Hoshino H, Matsuyama Y. The cohort study for the determination of reference values for spinopelvic parameters (T1 pelvic angle and global tilt) in elderly volunteers. *Eur Spine J* 2016;25:3687-93. <https://doi.org/10.1007/s00586-016-4411-x>.
- [6] Baxter RM, Macdonald DW, Kurtz SM, Steinbeck MJ. Severe impingement of lumbar disc replacements increases the functional biological activity of polyethylene wear debris. *J Bone Joint Surg Am* 2013;95:e751-9. <https://doi.org/10.2106/JBJS.K.00522>.
- [7] Beatty S. We Need to Talk about Lumbar Total Disc Replacement. *Int J Spine Surg* 2018;12:201-40. <https://doi.org/10.14444/5029>.
- [8] Berry MR, Peterson BG, Alander DH. A granulomatous mass surrounding a Maverick total disc replacement causing iliac vein occlusion and spinal stenosis: a case report. *J Bone Joint Surg Am* 2010;92:1242-5. <https://doi.org/10.2106/JBJS.H.01625>.
- [9] Bertagnoli R, Zigler J, Karg A, Voigt S. Complications and strategies for revision surgery in total disc replacement. *Orthop. Clin. North Am.* 2005;36:389-95. <https://doi.org/10.1016/j.joc.2005.03.003>.
- [10] Bifulco P, Cesarelli M, Cerciello T, Romano M. A continuous description of intervertebral motion by means of spline interpolation of kinematic data extracted by videofluoroscopy. *J Biomech* 2012;45:634-41. <https://doi.org/10.1016/j.jbiomech.2011.12.022>.
- [11] Bonnheim NB, Keaveny TM. Load-transfer in the human vertebral body following lumbar total disc arthroplasty: effects of implant size and stiffness in axial compression and forward flexion. *JOR Spine* 2020;3:e1078. <https://doi.org/10.1002/jsp2.1078>.
- [12] Botolin S, Puttlitz C, Baldini T, Petrella A, Burger E, Abjornson C, et al. Facet joint biomechanics at the treated and adjacent levels after total disc replacement. *Spine* 2011;36:E27-32. <https://doi.org/10.1097/BRS.0b013e3181d2d071>.
- [13] Brenke C, Schmieder K, Barth M. Core herniation after implantation of a cervical artificial disc: case report. *Eur Spine J* 2015;24(Suppl 4):S536-9. <https://doi.org/10.1007/s00586-014-3677-0>.
- [14] Brinjikji W, Diehn FE, Jarvik JG, Carr CM, Kallmes DF, Murad MH, et al. MRI Findings of Disc Degeneration are More Prevalent in Adults with Low Back Pain than in Asymptomatic Controls: a Systematic Review and Meta-Analysis. *AJNR Am J Neuroradiol* 2015;36:2394-9. <https://doi.org/10.3174/ajnr.A4498>.
- [15] Büttner-Janz K, Schellnack K, Zippel H. [An alternative treatment strategy in lumbar intervertebral disk damage using an SB Charité modular type intervertebral disk endoprosthesis]. *Z Orthop Ihre Grenzgeb* 1987;125:1-6. <https://doi.org/10.1055/s-2008-1039666>.
- [16] Choi J, Shin D-A, Kim S. Biomechanical Effects of the Geometry of Ball-and-Socket Artificial Disc on Lumbar Spine: a Finite Element Study. *Spine* 2017;42:E332-9. <https://doi.org/10.1097/BRS.0000000000001789>.
- [17] Cinotti G, David T, Postacchini F. Results of disc prosthesis after a minimum follow-up period of 2 years. *Spine* 1996;21:995-1000. <https://doi.org/10.1097/00007632-199604150-00015>.
- [18] Cui X-D, Li H-T, Zhang W, Zhang L-L, Luo Z-P, Yang H-L. Mid- to long-term results of total disc replacement for lumbar degenerative disc disease: a systematic review. *J Orthop Surg Res* 2018;13:326. <https://doi.org/10.1186/s13018-018-1032-6>.
- [19] de Maat GHR, Punt IM, van Rhijn LW, Schurink GWH, van Ooij A. Removal of the Charité lumbar artificial disc prosthesis: surgical technique. *J Spinal Disord Tech* 2009;22:334-9. <https://doi.org/10.1097/BSD.0b013e3181761d0c>.
- [20] Devin CJ, Myers TG, Kang JD. Chronic failure of a lumbar total disc replacement with osteolysis. Report of a case with nineteen-year follow-up. *J Bone Joint Surg Am* 2008;90:2230-4. <https://doi.org/10.2106/JBJS.G.01712>.
- [21] Dreischarf M, Schmidt H, Putzier M, Zander T. Biomechanics of the L5-S1 motion segment after total disc replacement - Influence of iatrogenic distraction, implant positioning and preoperative disc height on the range of motion and loading of facet joints. *J Biomech* 2015;48:3283-91. <https://doi.org/10.1016/j.jbiomech.2015.06.023>.
- [22] Eliasberg CD, Kelly MP, Ajiboye RM, SooHoo NF. Complications and Rates of Subsequent Lumbar Surgery Following Lumbar Total Disc Arthroplasty and Lumbar Fusion. *Spine* 2016;41:173-81. <https://doi.org/10.1097/BRS.0000000000001180>.
- [23] Enker P, Steffee A, Mcmillin C, Keppler L, Biscup R, Miller S. Artificial disc replacement. Preliminary report with a 3-year minimum follow-up. *Spine* 1993;18:1061-70.
- [24] Eskander MS, Onyedika II, Eskander JP, Connolly PJ, Eck JC, Lapinsky A. Revision strategy for posterior extrusion of the CHARITÉ polyethylene core. *Spine* 2010;35:E1430-4. <https://doi.org/10.1097/BRS.0b013e3181e9bf30>.
- [25] Farfan HF, Cossette JW, Robertson GH, Wells RV, Kraus H. The effects of torsion on the lumbar intervertebral joints: the role of torsion in the production of disc degeneration. *J Bone Joint Surg Am* 1970;52:468-97.
- [26] Fatoye F, Gebrye T, Odeyemi I. Real-world incidence and prevalence of low back pain using routinely collected data. *Rheumatol. Int.* 2019;39:619-26. <https://doi.org/10.1007/s00296-019-04273-0>.
- [27] Fernström U. Arthroplasty with intercorporeal endoprosthesis in herniated disc and in painful disc. *Acta Chir Scand Suppl* 1966;357:154-9.
- [28] Formica C, Zanirato A, Divano S, Basso M, Cavagnaro L, Alessio Mazzola M, Velone VG, Mastrogiacomo M, Berjano P, Felli L, Formica M. Total disc replacement for lumbar degenerative disc disease: single centre 20 years experience. *Eur Spine J* 2019. <https://doi.org/10.1007/s00586-019-06100-3>.
- [29] François J, Coessens R, Lauweryns P. Early removal of a Maverick disc prosthesis: surgical findings and morphological changes. *Acta Orthop Belg* 2007;73:122-7.
- [30] Franssen P, Pointillart V. Arthroplasty with the Bagueira Cervical Disc Prosthesis: a Review of the Scientific Background, Clinical and Radiographic Evidences. *J Spine Neurosurg* 2016;5. <https://doi.org/10.4172/2325-9701.1000247>.
- [31] Fraser RD, Ross ER, Lowery GL, Freeman BJ, Dolan M. AcroFLEX design and results. *Spine J* 2004;4:245S-251S. <https://doi.org/10.1016/j.spinee.2004.07.020>.
- [32] Gamradt SC, Wang JC. Lumbar disc arthroplasty. *Spine J* 2005;5:95-103. <https://doi.org/10.1016/j.spinee.2004.09.006>.
- [33] Geisler FH, Blumenthal SL, Guyer RD, McAfee PC, Regan JJ, Johnson JP, Mullin B. Neurological complications of lumbar artificial disc replacement and comparison of clinical results with those related to lumbar arthrodesis in the literature: results of a multicenter, prospective, randomized investigational device exemption study of Charité intervertebral disc. Invited submission from the Joint Section Meeting on Disorders of the Spine and Peripheral Nerves, March 2004. *J Neurosurg Spine* 2004;1:143-54. <https://doi.org/10.3171/spi.2004.1.2.0143>.
- [34] Gerometta A, Rodriguez Olaverri JC, Bittan F. Infection and revision strategies in total disc arthroplasty. *Int Orthop* 2012;36:471-4. <https://doi.org/10.1007/s00264-011-1436-y>.
- [35] Gragnaniello C, Seex KA, Eisermann LG, Claydon MH, Malham GM. Early postoperative dislocation of the anterior Maverick lumbar disc prosthesis: report of 2 cases. *J Neurosurg Spine* 2013;19:191-6. <https://doi.org/10.3171/2013.5.SPINE12753>.
- [36] Griffith SL, Shelokov AP, Büttner-Janz K, LeMaire JP, Zeegers WS. A multicenter retrospective study of the clinical results of the LINK SB Charité intervertebral prosthesis. The initial European experience. *Spine* 1994;19:1842-9. <https://doi.org/10.1097/00007632-199408150-00009>.
- [37] Hallab N, Link HD, McAfee PC. Biomaterial optimization in total disc arthroplasty. *Spine* 2003;28:S139-52. <https://doi.org/10.1097/01.BRS.0000092214.87225.80>.
- [38] Harrop JS, Youssef JA, Maltenfort M, Vorwald P, Jabbour P, Bono CM, et al. Lumbar adjacent segment degeneration and disease after arthrodesis and total disc arthroplasty. *Spine* 2008;33:1701-7. <https://doi.org/10.1097/BRS.0b013e31817bb956>.
- [39] Hashimoto K, Aizawa T, Kanno H, Itoi E. Adjacent segment degeneration after fusion spinal surgery-a systematic review. *Int Orthop* 2019;43:987-93. <https://doi.org/10.1007/s00264-018-4241-z>.
- [40] Hauer T, Thorwarth K, Thorwarth G. An overview on diamond-like carbon coatings in medical applications. Surface and Coatings Technology. Mechanical and Tribological Properties of Biomedical Coatings and Surface-modified Biomaterials 2013;233:119-30. <https://doi.org/10.1016/j.surfcoat.2013.04.015>.

- [41] Hellum C, Berg L, Gjertsen Ø, Johnsen LG, Neckelmann G, Storheim K, et al. Adjacent level degeneration and facet arthropathy after disc prosthesis surgery or rehabilitation in patients with chronic low back pain and degenerative disc: second report of a randomized study. *Spine* 2012;37:2063–73. <https://doi.org/10.1097/BRS.0b013e318263cc46>.
- [42] Hu X, Li K. [Stress changes of upper lumbar facet joint after discectomy and artificial disc replacement]. *Zhongguo Xiu Fu Chong Jian Wai Ke Za Zhi* 2005;19:427–30.
- [43] Huang RC, Tropiano P, Marnay T, Girardi FP, Lim MR, Cammisia FP. Range of motion and adjacent level degeneration after lumbar total disc replacement. *Spine J* 2006;6:242–7. <https://doi.org/10.1016/j.spinee.2005.04.013>.
- [44] Iannuzzi A, Pickar JG, Khalsa PS. Determination of torque-limits for human and cat lumbar spine specimens during displacement-controlled physiological motions. *Spine J* 2009;9:77–86. <https://doi.org/10.1016/j.spinee.2007.07.391>.
- [45] Inoue M, Mizuno T, Sakakibara T, Kato T, Yoshikawa T, Inaba T, Kasai Y. Trajectory of instantaneous axis of rotation in fixed lumbar spine with instrumentation. *J Orthop Surg Res* 2017;12. <https://doi.org/10.1186/s13018-017-0677-x>.
- [46] Kafchitsas K, Kokkinakis M, Habermann B, Rauschmann M. Effect of lumbar disc replacement on the height of the disc space and the geometry of the facet joints: a cadaver study. *J Bone Joint Surg Br* 2010;92:595–601. <https://doi.org/10.1302/0301-620X.92B4.23175>.
- [47] Kalakoti P, Missios S, Maiti T, Konar S, Bir S, Bollam P, et al. Inpatient Outcomes and Postoperative Complications After Primary Versus Revision Lumbar Spinal Fusion Surgeries for Degenerative Lumbar Disc Diseases: a National (Nation-wide) Inpatient Sample Analysis, 2002–2011. *World Neurosurg* 2016;85:114–24. <https://doi.org/10.1016/j.wneu.2015.08.020>.
- [48] Katz V, Schofferman J, Reynolds J. The sacroiliac joint: a potential cause of pain after lumbar fusion to the sacrum. *J Spinal Disord Tech* 2003;16:96–9. <https://doi.org/10.1097/00024720-200302000-00015>.
- [49] Kim JY, Ryu DS, Paik HK, Ahn SS, Kang MS, Kim KH, Park JY, Chin DK, Kim KS, Cho YE, Kuh SU. Paraspinal muscle, facet joint, and disc problems: risk factors for adjacent segment degeneration after lumbar fusion. *Spine J* 2016;16:867–75. <https://doi.org/10.1016/j.spinee.2016.03.010>.
- [50] Kim Y-K, Kang D, Lee I, Kim S-Y. Differences in the Incidence of Symptomatic Cervical and Lumbar Disc Herniation According to Age, Sex and National Health Insurance Eligibility: a Pilot Study on the Disease's Association with Work. *Int J Environ Res Public Health* 2018;15. <https://doi.org/10.3390/ijerph15102094>.
- [51] Ko S, Vaccaro AR, Lee S, Lee J, Chang H. The prevalence of lumbar spine facet joint osteoarthritis and its association with low back pain in selected Korean populations. *Clin Orthop Surg* 2014;6:385–91. <https://doi.org/10.4055/cios.2014.6.4.385>.
- [52] Kostuik JP. Complications and surgical revision for failed disc arthroplasty. *Spine J* 2004;4:289S–291S. <https://doi.org/10.1016/j.spinee.2004.07.021>.
- [53] Kurtz SM, Pelozo J, Siskey R, Villarraga ML. Analysis of a retrieved polyethylene total disc replacement component. *Spine J* 2005;5:344–50. <https://doi.org/10.1016/j.spinee.2004.11.011>.
- [54] Kurtz SM, van Ooij A, Ross R, de Waal Malefijt J, Pelozo J, Ciccarelli L, Villarraga ML. Polyethylene wear and rim fracture in total disc arthroplasty. *Spine J* 2007;7:12–21. <https://doi.org/10.1016/j.spinee.2006.05.012>.
- [55] Lackey A, Phan K, Mobbs R. A systematic review and meta-analysis of outcomes in hybrid constructs for multi-level lumbar degenerative disc disease. *J Clin Neurosci* 2016;34:23–9. <https://doi.org/10.1016/j.jocn.2016.06.011>.
- [56] Le Huec JC, Hasegawa K. Normative values for the spine shape parameters using 3D standing analysis from a database of 268 asymptomatic Caucasian and Japanese subjects. *Eur Spine J* 2016;25:3630–7. <https://doi.org/10.1007/s00586-016-4485-5>.
- [57] Lee CK, Goel VK. Artificial disc prosthesis: design concepts and criteria. *Spine J* 2004;4:209S–218S. <https://doi.org/10.1016/j.spinee.2004.07.011>.
- [58] LeHuec JC, Kiaer T, Friesem T, Mathews H, Liu M, Eisermann L. Shock absorption in lumbar disc prosthesis: a preliminary mechanical study. *J Spinal Disord Tech* 2003;16:346–51. <https://doi.org/10.1097/00024720-200308000-00006>.
- [59] Lei D, Holder RL, Smith FW, Wardlaw D, Hukins DWL. Cluster analysis as a method for determining size ranges for spinal implants: disc lumbar replacement prosthesis dimensions from magnetic resonance images. *Spine* 2006;31:2979–83. discussion 2984. <https://doi.org/10.1097/01.brs.0000248414.62802.42>.
- [60] Link HD. History, design and biomechanics of the LINK SB Charité artificial disc. *Eur Spine J* 2002;11(Suppl 2):S98–S105. <https://doi.org/10.1007/s00586-002-0475-x>.
- [61] Lu S, Sun S, Kong C, Sun W, Hu H, Wang Q, Hai Y. Long-term clinical results following Charité III lumbar total disc replacement. *Spine J* 2018;18:917–25. <https://doi.org/10.1016/j.spinee.2017.08.252>.
- [62] Michael AP, Weber MW, Delfino KR, Ganapathy V. Adjacent-segment disease following two-level axial lumbar interbody fusion. *J Neurosurg Spine* 2019;1:8. <https://doi.org/10.3171/2019.2.SPINE18929>.
- [63] Murtagh RD, Quencer RM, Cohen DS, Yue JJ, Sklar EL. Normal and abnormal imaging findings in lumbar total disc replacement: devices and complications. *Radiographics* 2009;29:105–18. <https://doi.org/10.1148/rg.291075740>.
- [64] Nakashima H, Kawakami N, Tsuji T, Ohara T, Suzuki Y, Saito T, et al. Adjacent Segment Disease After Posterior Lumbar Interbody Fusion: based on Cases With a Minimum of 10 Years of Follow-up. *Spine* 2015;40:E831–41. <https://doi.org/10.1097/BRS.0000000000000917>.
- [65] Nayak AN, Doarn MC, Gaskins RB, James CR, Cabezas AF, Castellvi AE, Santoni BG. Postero-lateral disc prosthesis combined with a unilateral facet replacement device maintains quantity and quality of motion at a single lumbar level. *Int J Spine Surg* 2014;8. <https://doi.org/10.14444/1031>.
- [66] Oichi T, Taniguchi Y, Oshima Y, Tanaka S, Saito T. Pathomechanism of intervertebral disc degeneration. *JOR Spine* 2020;3:e1076. <https://doi.org/10.1002/jsp2.1076>.
- [67] Page A, Candelas P, Belmar F. On the use of local fitting techniques for the analysis of physical dynamic systems. *European J Physics* 2006;27:273–9.
- [68] Page A, De Rosario H, Mata V, Atienza CM. Experimental Analysis of Rigid Body Motion. A Vector Method to Determine Finite and Infinitesimal Displacements From Point Coordinates. *J Mechanical Design* 2009;131:1–8.
- [69] Page A, De Rosario H, Mata V, Hoyos JV, Porcar R. Effect of marker cluster design on the accuracy of human movement analysis using stereophotogrammetry. *Med Biol Eng Comput* 2006;44:1113–19. <https://doi.org/10.1007/s11517-006-0124-3>.
- [70] Page A, Galvez JA, de Rosario H, Mata V, Prat J. Optimal average path of the instantaneous helical axis in planar motions with one functional degree of freedom. *J Biomech* 2010;43:375–8. <https://doi.org/10.1016/j.jbiomech.2009.09.023>.
- [71] Park C-K, Ryu K-S, Jee W-H. Degenerative changes of discs and facet joints in lumbar total disc replacement using ProDisc II: minimum two-year follow-up. *Spine* 2008;33:1755–61. <https://doi.org/10.1097/BRS.0b013e31817b8fed>.
- [72] Patwardhan AG, Havey RM, Wharton ND, Tsiopoulos PP, Newman P, Carandang G, Voronov LI. Asymmetric motion distribution between components of a mobile-core lumbar disc prosthesis: an explanation of unequal wear distribution in explanted CHARITÉ polyethylene cores. *J Bone Joint Surg Am* 2012;94:846–54. <https://doi.org/10.2106/JBJS.J.00638>.
- [73] Pfirrmann CW, Metzdorf A, Zanetti M, Hodler J, Boos N. Magnetic resonance classification of lumbar intervertebral disc degeneration. *Spine* 2001;26:1873–8. <https://doi.org/10.1097/00007632-200109010-00011>.
- [74] Pimenta L, Díaz RC, Guerrero LG. Charité lumbar artificial disc retrieval: use of a lateral minimally invasive technique. Technical note. *J Neurosurg Spine* 2006;5:556–61. <https://doi.org/10.3171/spi.2006.5.6.556>.
- [75] Punt I, van Rijsbergen M, van Rietbergen B, Ito K, van Rhijn L, van Ooij A, Willems P. Subsidence of SB Charité total disc replacement and the role of undersizing. *Eur Spine J* 2013;22:2264–70. <https://doi.org/10.1007/s00586-013-2864-8>.
- [76] Punt IM, Visser VM, van Rhijn LW, Kurtz SM, Antonis J, Schurink GWH, van Ooij A. Complications and reoperations of the SB Charité lumbar disc prosthesis: experience in 75 patients. *Eur Spine J* 2008;17:36–43. <https://doi.org/10.1007/s00586-007-0506-8>.
- [77] Ren C, Song Y, Liu L, Xue Y. Adjacent segment degeneration and disease after lumbar fusion compared with motion-preserving procedures: a meta-analysis. *Eur J Orthop Surg Traumatol* 2014;24(Suppl 1):S245–53. <https://doi.org/10.1007/s00590-014-1445-9>.
- [78] Rodríguez-Soto AE, Berry DB, Palombo L, Valaik E, Kelly KR, Ward SR. Effect of Load Magnitude and Distribution on Lumbar Spine Posture in Active-duty Marines. *Spine* 2017;42:345–51. <https://doi.org/10.1097/BRS.0000000000001742>.
- [79] Rohlmann A, Lauterborn S, Dreischarf M, Schmidt H, Putzier M, Strube P, Zander T. Parameters influencing the outcome after total disc replacement at the lumbosacral junction. Part 1: misalignment of the vertebrae adjacent to a total disc replacement affects the facet joint and facet capsule forces in a probabilistic finite element analysis. *Eur Spine J* 2013;22:2271–8. <https://doi.org/10.1007/s00586-013-2909-z>.
- [80] Rohlmann A, Mann A, Zander T, Bergmann G. Effect of an artificial disc on lumbar spine biomechanics: a probabilistic finite element study. *Eur Spine J* 2009;18:89–97. <https://doi.org/10.1007/s00586-008-0836-1>.
- [81] Ross R, Mirza AH, Norris HE, Khatri M. Survival and clinical outcome of SB Charité III disc replacement for back pain. *J Bone Joint Surg Br* 2007;89:785–9. <https://doi.org/10.1302/0301-620X.89B6.18806>.
- [82] Rousseau M-A, Bradford DS, Bertagnoli R, Hu SS, Lotz JC. Disc arthroplasty design influences intervertebral kinematics and facet forces. *Spine J* 2006;6:258–66. <https://doi.org/10.1016/j.spinee.2005.07.004>.
- [83] Rousseau M-A, Bradford DS, Hadi TM, Pedersen KL, Lotz JC. The instant axis of rotation influences facet forces at L5/S1 during flexion/extension and lateral bending. *Eur Spine J* 2006;15:299–307. <https://doi.org/10.1007/s00586-005-0935-1>.
- [84] Sasso RC, Foulk DM, Hahn M. Prospective, randomized trial of metal-on-metal artificial lumbar disc replacement: initial results for treatment of discogenic pain. *Spine* 2008;33:123–31. <https://doi.org/10.1097/BRS.0b013e31816043af>.
- [85] Schätz C, Ritter-Lang K, Gössel L, Dreßler N. Comparison of Single-Level and Multiple-Level Outcomes of Total Disc Arthroplasty: 24-Month Results. *Int J Spine Surg* 2015;9:14. <https://doi.org/10.14444/2014>.
- [86] Schmidt H, Galbusera F, Rohlmann A, Zander T, Wilke H-J. Effect of multilevel lumbar disc arthroplasty on spine kinematics and facet joint loads in flexion and extension: a finite element analysis. *Eur Spine J* 2012;21(Suppl 5):S663–74. <https://doi.org/10.1007/s00586-010-1382-1>.
- [87] Schmidt H, Heuer F, Claes L, Wilke H-J. The relation between the instantaneous center of rotation and facet joint forces - A finite element analysis. *Clin Biomech (Bristol, Avon)* 2008;23:270–8. <https://doi.org/10.1016/j.clinbiomech.2007.10.001>.
- [88] Schmidt H, Middelhoff S, Adkins K, Wilke H-J. The effect of different design concepts in lumbar total disc arthroplasty on the range of motion, facet joint forces and instantaneous center of rotation of a L4–5 segment. *Eur Spine J* 2009;18:1695–705. <https://doi.org/10.1007/s00586-009-1146-y>.
- [89] Serhan H, Mhatre D, Defosse H, Bono CM. Motion-preserving technologies for degenerative lumbar spine: the past, present, and future horizons. *SAS J* 2011;5:75–89. <https://doi.org/10.1016/j.esas.2011.05.001>.
- [90] Serra T, Capelli C, Toumpaniari R, Orriss IR, Leong JHH, Dalgarno K, et al. Design and fabrication of 3D-printed anatomically shaped lumbar cage for intervertebral disc (IVD) degeneration treatment. *Biofabrication* 2016;8:035001. <https://doi.org/10.1088/1758-5090/8/3/035001>.
- [91] Shim CS, Lee S, Maeng DH, Lee S-H. Vertical split fracture of the vertebral body following total disc replacement using ProDisc: report of two cases. *J Spinal Disord Tech* 2005;18:465–9. <https://doi.org/10.1097/01.bsd.0000159035.35365.df>.
- [92] Shim CS, Lee S-H, Shin H-D, Kang HS, Choi W-C, Jung B, et al. CHARITÉ versus ProDisc: a comparative study of a minimum 3-year follow-up. *Spine* 2007;32:1012–18. <https://doi.org/10.1097/01.brs.0000260795.57798.a0>.

- [93] Shin MH, Ryu KS, Rathi NK, Park CK. Segmental translation after lumbar total disc replacement using Prodisc-L®: associated factors and relation to facet arthrosis. *J Neurosurg Sci* 2017;61:14–21. <https://doi.org/10.23736/S0390-5616.16.03135-0>.
- [94] Siepe CJ, Heider F, Wiechert K, Hitzl W, Ishak B, Mayer MH. Mid-to long-term results of total lumbar disc replacement: a prospective analysis with 5- to 10-year follow-up. *Spine J* 2014;14:1417–31. <https://doi.org/10.1016/j.spinee.2013.08.028>.
- [95] Siepe CJ, Zelenkov P, Sauri-Barraza J-C, Szeimies U, Grubinger T, Tepass A, et al. The fate of facet joint and adjacent level disc degeneration following total lumbar disc replacement: a prospective clinical, X-ray, and magnetic resonance imaging investigation. *Spine* 2010;35:1991–2003. <https://doi.org/10.1097/BRS.0b013e3181d6f878>.
- [96] Singer A. Osteoporosis diagnosis and screening. *Clin Cornerstone* 2006;8:9–18. [https://doi.org/10.1016/s1098-3597\(06\)80061-x](https://doi.org/10.1016/s1098-3597(06)80061-x).
- [97] Skrzypiec DM, Bishop NE, Klein A, Püschel K, Morlock MM, Huber G. Estimation of shear load sharing in moderately degenerated human lumbar spine. *J Biomech* 2013;46:651–7. <https://doi.org/10.1016/j.jbiomech.2012.11.050>.
- [98] Stolworthy DK, Zirbel SA, Howell LL, Samuels M, Bowden AE. Characterization and prediction of rate-dependent flexibility in lumbar spine biomechanics at room and body temperature. *Spine J* 2014;14:789–98. <https://doi.org/10.1016/j.spinee.2013.08.043>.
- [99] Sullivan HG, Bertagnoli R, Nigogosyan MA, Ladwig NR, Born HL, Cerniglia MM, Habbicht H, Mathiason MA, McHugh VL. Prevention of vertebral body-splitting fractures after multilevel ProDisc-L implantation. *Int J Spine Surg* 2012;6:93–102. <https://doi.org/10.1016/j.ijsp.2011.12.004>.
- [100] Valdevit A, Errico TJ. Design and evaluation of the FlexiCore metal-on-metal intervertebral disc prosthesis. *Spine J* 2004;4:276S–288S. <https://doi.org/10.1016/j.spinee.2004.07.016>.
- [101] van Ooij A, Kurtz SM, Stessels F, Noten H, van Rhijn L. Polyethylene wear debris and long-term clinical failure of the Charité disc prosthesis: a study of 4 patients. *Spine* 2007;32:223–9. <https://doi.org/10.1097/01.brs.0000251370.56327.c6>.
- [102] van Ooij A, Oner FC, Verbout AJ. Complications of artificial disc replacement: a report of 27 patients with the SB Charité disc. *J Spinal Disord Tech* 2003;16:369–83. <https://doi.org/10.1097/00024720-200308000-00009>.
- [103] Veruva SY, Lanman TH, Isaza JE, Freeman TA, Kurtz SM, Steinbeck MJ. Periprosthetic UHMWPE Wear Debris Induces Inflammation, Vascularization, and Innervation After Total Disc Replacement in the Lumbar Spine. *Clin. Orthop. Relat. Res.* 2017;475:1369–81. <https://doi.org/10.1007/s11999-016-4996-8>.
- [104] Veruva SY, Steinbeck MJ, Toth J, Alexander DD, Kurtz SM. Which design and biomaterial factors affect clinical wear performance of total disc replacements? A systematic review. *Clin. Orthop. Relat. Res.* 2014;472:3759–69. <https://doi.org/10.1007/s11999-014-3751-2>.
- [105] Volkheimer D, Malakoutian M, Oxland TR, Wilke H-J. Limitations of current in vitro test protocols for investigation of instrumented adjacent segment biomechanics: critical analysis of the literature. *Eur Spine J* 2015;24:1882–92. <https://doi.org/10.1007/s00586-015-4040-9>.
- [106] Werner JH, Rosenberg JH, Keeley KL, Agrawal DK. Immunobiology of periprosthetic inflammation and pain following ultra-high-molecular-weight-polyethylene wear debris in the lumbar spine. *Expert Rev Clin Immunol* 2018;14:695–706. <https://doi.org/10.1080/1744666X.2018.1511428>.
- [107] Wilke H-J, Schmidt R, Richter M, Schmoelz W, Reichel H, Cakir B. The role of prosthesis design on segmental biomechanics: semi-constrained versus unconstrained prostheses and anterior versus posterior centre of rotation. *Eur Spine J* 2012;21(Suppl 5):S577–84. <https://doi.org/10.1007/s00586-010-1552-1>.
- [108] Wininger KL, Deshpande KK, Bester ML. Persistent pain following lumbar disc replacement. *Radiol Technol* 2012;83:430–6.
- [109] Woltring HJ, Long K, Osterbauer PJ, Fuhr AW. Instantaneous helical axis estimation from 3-D video data in neck kinematics for whiplash diagnostics. *J Biomech* 1994;27:1415–32. [https://doi.org/10.1016/0021-9290\(94\)90192-9](https://doi.org/10.1016/0021-9290(94)90192-9).
- [110] Wright TM. CORR Insights®: periprosthetic UHMWPE Wear Debris Induces Inflammation, Vascularization, and Innervation After Total Disc Replacement in the Lumbar Spine. *Clin. Orthop. Relat. Res.* 2017;475:1382–5. <https://doi.org/10.1007/s11999-016-5026-6>.
- [111] Yao Q, Wang JC, Shamie AN, Lord E, Cohen Y, Zheng S, et al. The effects of a semiconstrained integrated artificial disc on zygapophyseal joint pressure and displacement. *Spine* 2014;39:E1510–17. <https://doi.org/10.1097/BRS.0000000000000638>.
- [112] Yoshihara H. Sacroiliac joint pain after lumbar/lumbosacral fusion: current knowledge. *Eur Spine J* 2012;21:1788–96. <https://doi.org/10.1007/s00586-012-2350-8>.
- [113] Yoshioka T, Tsuji H, Hirano N, Sainoh S. Motion characteristic of the normal lumbar spine in young adults: instantaneous axis of rotation and vertebral center motion analyses. *J Spinal Disord* 1990;3:103–13.
- [114] Yukawa Y, Kato F, Suda K, Yamagata M, Ueta T, Yoshida M. Normative data for parameters of sagittal spinal alignment in healthy subjects: an analysis of gender specific differences and changes with aging in 626 asymptomatic individuals. *Eur Spine J* 2018;27:426–32. <https://doi.org/10.1007/s00586-016-4807-7>.
- [115] Zeegers WS, Bohnen LM, Laaper M, Verhaegen MJ. Artificial disc replacement with the modular type SB Charité III: 2-year results in 50 prospectively studied patients. *Eur Spine J* 1999;8:210–17. <https://doi.org/10.1007/s005860050160>.
- [116] Zhong Z-M, Deviren V, Tay B, Burch S, Berven SH. Adjacent segment disease after instrumented fusion for adult lumbar spondylolisthesis: incidence and risk factors. *Clin Neurol Neurosurg* 2017;156:29–34. <https://doi.org/10.1016/j.clineuro.2017.02.020>.
- [117] Zigler J, Gornet MF, Ferko N, Cameron C, Schranck FW, Patel L. Comparison of Lumbar Total Disc Replacement With Surgical Spinal Fusion for the Treatment of Single-Level Degenerative Disc Disease: a Meta-Analysis of 5-Year Outcomes From Randomized Controlled Trials. *Global Spine J* 2018;8:413–23. <https://doi.org/10.1177/2192568217737317>.
- [118] Zirbel SA, Stolworthy DK, Howell LL, Bowden AE. Intervertebral disc degeneration alters lumbar spine segmental stiffness in all modes of loading under a compressive follower load. *Spine J* 2013;13:1134–47. <https://doi.org/10.1016/j.spinee.2013.02.010>.