

Bionate Biocompatibility: In Vivo Study in Rabbits

Amparo Vanaclocha-Saiz, Vicente Vanaclocha,* Carlos Atienza, Pablo Jorda-Gomez, Víctor Primo-Capella, Carlos Barrios, and Leyre Vanaclocha



Cite This: *ACS Omega* 2022, 7, 29647–29654



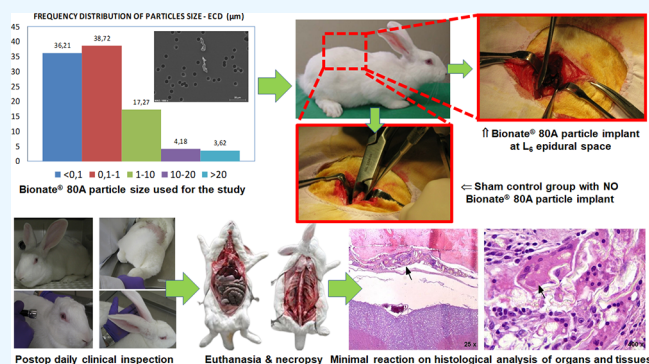
Read Online

ACCESS |

Metrics & More

Article Recommendations

ABSTRACT: Response to foreign materials includes local tissue reaction, osteolysis, implant loosening, and migration to lymph nodes and organs. Bionate 80A human explants show minor wear and slight local tissue reaction, but we do not know the response at the spinal cord, nerve roots, lymph nodes, or distant organs. This study aims to figure out reactions against Bionate 80A when implanted at the spinal epidural space of 24 20-week-old New Zealand white rabbits. In one group of 12 rabbits, we implanted Bionate 80A on the spinal epidural space, and another group of 12 rabbits was used as the control group. We studied tissues, organs, and tissue damage markers on blood biochemistry, urine tests, and necropsy. The animals' clinical parameters and weight showed no statistically significant differences. At 3 months, the basophils increased slightly in the implant group, platelets decreased in all, and at 6 months, implanted animals showed slight eosinophilia, but none of these changes was statistically significant. External, organ, and spinal tissue examination showed neither toxic reaction, inflammatory changes, or noticeable differences between groups or survival periods. Under microscopic examination, the Bionate 80A particles induced a chronic granulomatous response always outside the *dura mater*, with giant multinucleated cells holding phagocytized particles and no particle migration to lymph nodes or organs. Thus, it was concluded that Bionate particles, when implanted in the rabbit lumbar epidural space, do not generate a significant reaction limited to the surrounding soft tissues with giant multinucleated cells. In addition, the particles did not cross the *dura mater* or migrate to lymph nodes or organs.



INTRODUCTION

Body response to implanted foreign materials and their wear and tear particles¹ is known particularly in devices with movable pieces, such as in major joint arthroplasty.² The particles and metallic ions can induce local tissue reactions with osteolysis³ and implant loosening,⁴ migrate through the regional lymph nodes,⁵ and reach distant organs (liver and spleen).⁶ The number and size of those particles correlate with the probability of these unwanted events.⁷ This response is particularly severe with ultrahigh molecular weight polyethylene (UHMWPE),⁸ less with metallic alloys^{9,10} and minimal with polymeric materials,¹ particularly polycarbonate urethanes (PCU).¹¹ These latter materials have a negligible wear rate, generating fewer but larger particles than other polymeric materials.^{12,13} That correlates with a more limited macrophage response¹⁴ and minimal osteolytic capacity.^{11,15}

The PCU Bionate 80A (a polycarbonate urethane from Polymer Technology Group, Inc., Sunnyvale, CA, USA) has shown excellent mechanical resistance and biocompatibility both *in vitro*^{16–19} and *in vivo*.²⁰ However, hip acetabular articular cartilage substitution with this material in sheep has a slight long-term wear and tear rate^{20,21} with minor superficial cracks and limited particle liberation.²² The mechanically resistant and

biocompatible properties are present in its bulk form, but we are unsure about its effects in particulate form. Additionally, we know that sterilization affects its chemical composition^{12,19,23} and mechanical resistance²³ as it induces chain scission and cross-linking^{24–26} with the liberation of other chemical products like *N,N'*-methylene dianiline.²⁷

Human data come from explanted implants containing Bionate 80A (Bryan cervical disc and Dynesis lumbar dynamic stabilization). In both cases, wear particles and local tissue reactions were negligible, but nobody studied lymph node or distant organ migration as these implants came from live patients and not postmortem studies. Additionally, and for the same reason, no data is available on the possible reaction to nearby nervous structures (spinal cord or nerve roots).

After literature research, we found no publications about body reactions against Bionate 80A reaction when implanted in

Received: March 20, 2022

Accepted: August 10, 2022

Published: August 19, 2022



particulate form at the lumbar spine epidural space, a gap this study intended to cover. The data obtained will be a step before the clinical application of a Bionate 80A discal nucleus replacement previously published.²⁸

MATERIALS AND METHODS

We followed UNE-EN ISO 10993-6:2007,²⁹ UNE-ISO 10993-11:2006,³⁰ and ASTM F 763-04³¹ for experimental design, surgical procedure, and data analysis. The Ethical Committee from the Polytechnic University of Valencia, Spain, approved this study and certified that we performed the experiments according to national and local guidelines and regulations.

Using ultrapure water, we obtained the Bionate 80A particles through the "pin-on-cylinder" wear technique²¹ using a polyurethane piece pressed under a constant 50 N force against a rotating metallic cylinder (Figure 1), an equipment developed




Figure 1. Pin-on-cylinder wear technique. F = force (50 N).

at the Institute of Biomechanics of Valencia (IBV), Spain, using ultrapure water as the fluid test medium. We extracted the particle samples from the test fluid and filtered and analyzed it by SEM (scanning electron microscopy) for their size characterization. Most of the particles obtained are smaller than 1 μm (75%). Ninety-two percent of the particles are smaller than 10 μm , which is the size limit for a particle to be phagocytatable by the cells,⁷ thus being susceptible to producing biological reactions (Figure 2).

We undertook the study in the BV with methods and facilities approved by the Dirección General de Producción Agraria de la

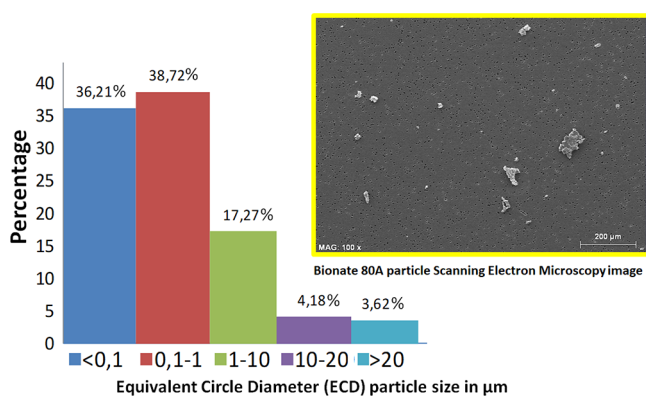


Figure 2. Particle size distribution according to the equivalent circle diameter (ECD) with the pin-on-cylinder wear technique and analyzed by SEM (shown in the image above the chart).

Consellería de Agricultura, Pesca, y Alimentación under registry number ES 4625000010006. Throughout the study, we followed Spanish animal research laws.³²

We selected 20-week-old nullipara female, parasite-free New Zealand white rabbits for the study, weighing each animal and measuring its food consumption daily.

We submitted 24 animals to the same surgical procedure. In 12, we implanted a Bionate 80A particle sample at the L₆ epidural space, and in another 12 (control group), we inserted no foreign material. Then, we split both groups into two subgroups of six animals each, with 3 and 6 month survival, respectively.

For pre-anesthesia and after weighing each animal, we administered xylazine 2% (2.5 mg/kg) and ketamine hydrochloride (17.5 mg/kg) as well as an antibiotic, enrofloxacin (3.5 mg/kg), all intramuscularly. Next, we administered intravenous propofol 1% in a marginal ear vein with an initial dose of 3 mg/kg, followed by continuous infusion (21 mg/kg/h).

We placed the rabbit in the prone position, shaved the lumbar area with an electrical clipper, scrubbed it with povidone iodine, and sprayed it with a mixture of povidone iodine and 80% ethanol.

Under aseptic conditions, we made a midline lumbar 4 cm incision, exposed the L₅ and L₆ spinous processes, excised the latter, and removed the *ligamentum flavum* at the L₅–L₆ interspace, accessing the epidural space. We then implanted a gamma radiation sterilized Bionate 80A 0.7 mm³ (=0.8 mg) powder particle sample in the epidural space at the junction between the nerve root and thecal sac. The gamma sterilization used 2.5 Mrad in a gamma cell 220 Co-irradiating Unit (IONISOS Ibérica, Tarancón, Spain). The control group's surgical technique was identical but without particle implantation. Finally, we closed the incision in the muscle, subcutaneous tissue, and skin layers.

For 3 days post-operation, we administered meglumine (anti-inflammatory, 1 mg/kg/day, subcutaneously), butorfanol (analgesic, 0.4 mg/kg/day, intramuscularly), and enrofloxacin (antibiotic, 0.4 mL/kg/day, intramuscularly).

Post-operation rabbits ate *ad libitum* and moved freely inside their cages. We weighed them and controlled their food intake daily, following ASTM F750.³³

We inspected the rabbits' skin, fur, eyes, mucous membranes, secretions, excretions, autonomic activity, gait, posture, response to handling, clonic or tonic movements, stereotypes, or any bizarre behavior daily (ISO-10993-11³⁰) (Figure 3).

Table 1 details the parameters controlled during these inspections.

We requested blood biochemistry tests pre- and post-operation at monthly intervals and before euthanasia, looking for toxic effects in tissues, kidneys, liver, and tissue damage markers.

We euthanized the animals with a sodium pentobarbital overdose (100 mg/kg) administered through an ear vein.

After sacrifice, we submitted each animal to a complete necropsy (Figure 4), including external and internal exams. We looked at their fur and natural orifices as well as their cranial, thoracic, and abdominal cavities and its contents.

We opened the rib cage and abdominal cavity, observed the general aspect, clamped the esophagus and rectum, and removed the abdominal contents.

We visually examined their thoracic and abdominal cavities, looking for injury signs or organic liquids. Next, we compared the size, color, and appearance of the implanted rabbits' spinal




Figure 3. Toxicity study clinical inspection parameters: (a) behavior and posture, (b) leg extension reflex, (c) pupillary light reflex, and (d) ears pricking up.

Table 1. Toxicity Clinical Parameters Evaluated

ANIMAL NUMBER:				
DATE				
Weight:	Breath frequency			Wound
CLINICAL PARAMETERS	Normal	Modified	Abnormal	Observations
Behavior				
Locomotion				
Posture				
Trembling				
Convulsion				
Salivation				
Lethargy				
Diarrhea				
Back feeling				
Limbs feeling				
Pupillary light reflex				
Hind limb extension reflex				
Eat				
Drink				
Feces				
Urine				
Skin and fur				
Mucous membranes				
Ears				
Hind limbs trembling				
Weakness right hind limb				
Crawls				




Figure 4. Ventral and dorsal rabbit necropsy.

cord and organs to those of control animals. Finally, we incised the whole rabbit's back, observed the aspect of the dorsal

musculoskeletal structures, isolated the anatomical area where we had implanted the Bionate 80A particles, and removed it as a piece including the spine and spinal cord from L₅ to L₇.

Finally, we performed a histopathological examination in search of lesions in the brain, spinal cord, pituitary, eyes, thyroid, parathyroid, thymus, esophagus, salivary glands, stomach, small and large intestines, liver, gall bladder, pancreas, kidneys, adrenals, spleen, heart, trachea, lungs, aorta, ovaries, uterus, mammary gland, urinary bladder, lymph nodes, peripheral nerve, bone marrow, and skin.

We performed microscopic assessment in tissues from the implantation zone (spinal cord and surrounding tissues and musculoskeletal tissues from caudal to adjacent cranial zones from L₅ to L₇) and organs (kidneys, liver, and spleen).

We collected the kidneys, liver, spleen, and tissues surrounding the implanted Bionate 80A particles, including the muscles, epidural space, *dura mater*, nerve root, and L₅ and L₇ spinous processes. Then, we removed the Bionate 80A with sufficient unaffected surrounding tissue (ASTM F619³⁴) to evaluate the local response.

At the particle implantation site, we evaluated with a 0 to 5 scale (0 for no response, 5 for severe) the number and cell type and whether the reaction was focal or diffuse (ASTM F1904³⁵). We also analyzed the presence of particles in regional lymph nodes and distant organs and histological responses compared to the control animals.

We decalcified the L₅ and L₇ spinous processes (so we could slice them easily), preserved the organs and tissue samples in formaldehyde, included them in paraffin, sectioned them into 5 and 10 μm slices, and stained them with hematoxylin–eosin. Then, we looked at signs of cellular abnormalities, inflammatory reactions, hemorrhage, hemosiderin, adipocytic necrosis, macrophage, granulocyte, lymphocyte or plasmatic cells, or migration of implanted Bionate particles outside the implant zone, mainly if they had crossed the *dura mater*. We searched for migrated Bionate 80A particles in the organs and signs of cellular abnormality or inflammatory response. We studied the epidural space, *dura mater*, subdural space, and spinal cord, looking for signs of inflammatory reaction, hemorrhage, adipocytic necrosis, and the presence of macrophages, granulocytes, lymphocytes, and plasma cells as well as possible migration of released particles that could cross the *dura mater* and escape from the implant zone.

We also did a microscopical analysis of the Bionate particles that we could isolate from the implant side to see if they had undergone any material degradation.

STATISTICAL ANALYSIS

Once we obtained the data from all blood samples, we grouped them in an MS Excel (Microsoft Corporation, Redmond, WA, USA) sheet, which we also used to conduct statistical tests. We used the free statistical analysis software R (R Development Core Team) with Student's *t* tests to find statistically significant differences between the implanted and control rabbits. First, we used Student's *t* tests to find whether statistically significant differences existed between the implanted and control rabbits. Next, we compared these values with reported hemogram reference values for rabbits.³⁶ We considered a *p* value of <0.05 as statistically significant.

Table 2. Weight Changes in Kilograms during the Study (Means ± SD)

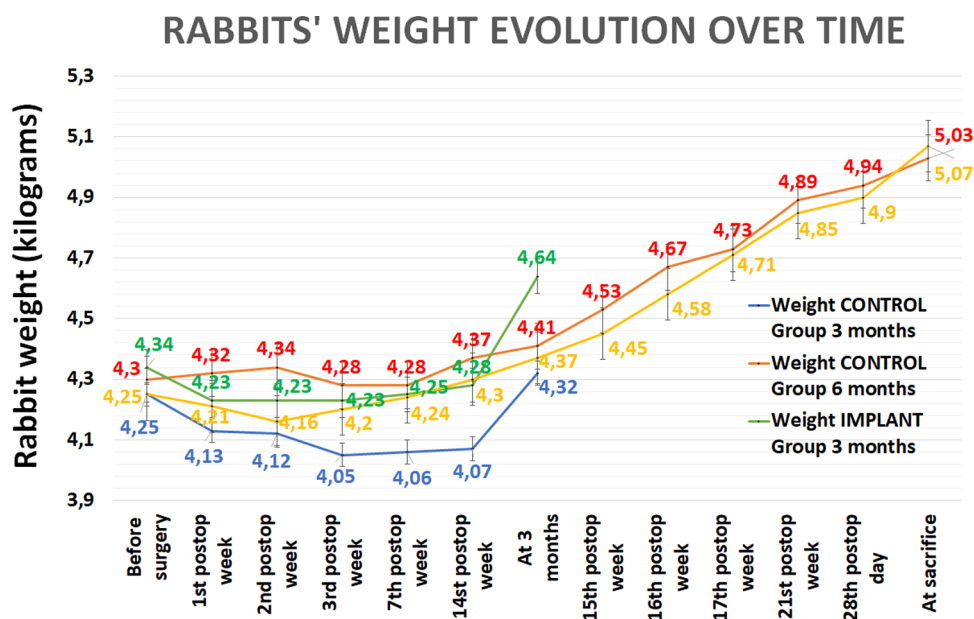
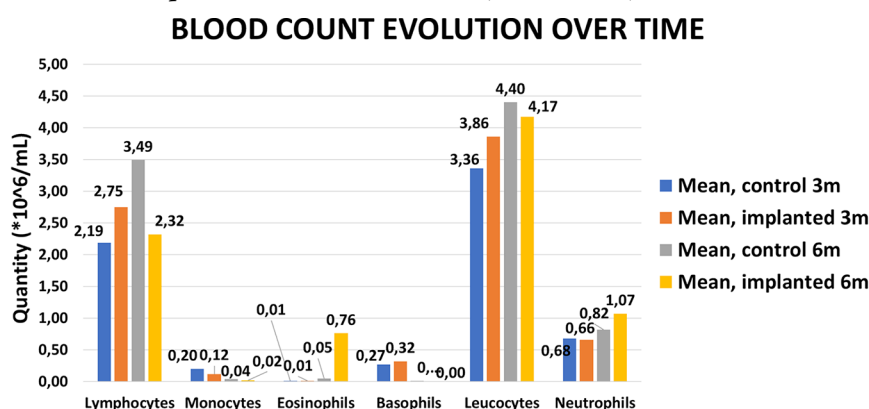


Table 3. Hemogram Results for the Implanted and Control Rabbits (Means ± SD)



BLOOD COUNT	3 months survival		6 months survival	
	CONTROL	IMPLANTED	CONTROL	IMPLANTED
Erithrocytes (*10 ⁶ /μL)	5.53 ± 0.44	5.42 ± 0.12	5.20 ± 0.64	5.43 ± 0.47
Hemoglobin (g/L)	114.33 ± 8.39	116.00 ± 4.58	119.00 ± 11.31	128.00 ± 13.89
Hematocrit (%)	38.00 ± 3.04	40.00 ± 1.73	34.00 ± 2.83	36.33 ± 4.04
Leucocytes (*10 ⁶ /mL)	3.36 ± 0.08	3.86 ± 1.73	4.40 ± 1.13	4.17 ± 0.64
Neutrophils (*10 ⁶ /mL)	0.68 ± 0.15	0.66 ± 0.21	0.82 ± 0.36	1.07 ± 0.87
% Neutrophils	20.23 ± 4.55	17.77 ± 3.33	20.30 ± 13.44	24.30 ± 18.24
Lymphocyte (*10 ⁶ /mL)	2.19 ± 0.05	2.75 ± 1.45	3.49 ± 1.51	2.32 ± 0.69
% Lymphocytes	65.33 ± 1.59	69.93 ± 5.17	77.45 ± 14.50	55.10 ± 11.49
Monocytes (*10 ⁶ /mL)	0.20 ± 0.05	0.12 ± 0.01	0.04 ± 0.01	0.02 ± 0.02
% Monocytes	5.93 ± 1.26	3.37 ± 1.10	0.90 ± 0.14	0.40 ± 0.26
Eosinophils (*10 ⁶ /mL)	0.01 ± 0.01	0.01 ± 0.01	0.05 ± 0.04	0.76 ± 1.09
% Eosinophils	0.40 ± 0.35	0.10 ± 0.17	1.25 ± 1.20	20.10 ± 29.55
Basophils (*10 ⁶ /mL)	0.27 ± 0.11	0.32 ± 0.07	0.01 ± 0.01	0.00 ± 0.01
% Basophils	8.10 ± 3.08	8.83 ± 2.05	0.10 ± 0.00	0.10 ± 0.17
Platelets (*10 ⁶ /mL)	86.67 ± 11.02	117.33 ± 27.23	235.50 ± 60.10	266.67 ± 24.68

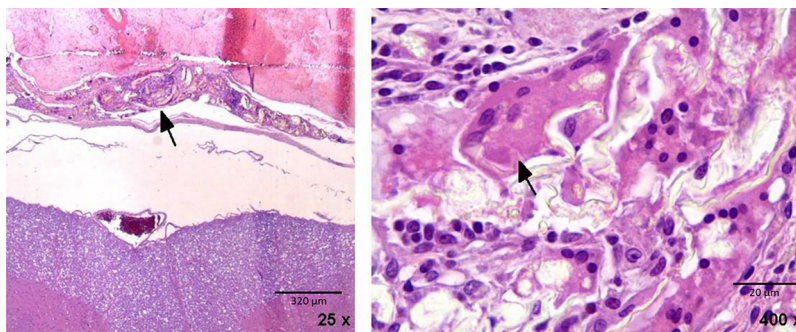


Figure 5. These two micrographs depict the inflammatory reaction caused by the Bionate particles (birefringent structures). The arrow points to this reaction on the left image, which is entirely extradural. On the right image, the indicator shows a giant multinucleated cell.

RESULTS

Animal Behavior Observations. The parameters most altered post-operation were the locomotion pattern, hind limb weakness and trembling, and decreased crawl reflex, which recovered gradually until it returned to preoperative status. The absence of statistically significant differences between groups indicates their relationship with the surgical procedure and not the implanted particles.

There was a tendency to lose weight on the second and third day post-surgery due to temporary anorexia, weakness, and discomfort. However, one week after surgery, all animals recovered their preoperative weight with no statistically significant differences between groups or survival periods (Table 2).

Blood Tests. We found no statistically significant differences between the control and implanted rabbits at 3 and 6 months post-operation (Table 3), and the mean values for the different parameters fell within the published ranges.³⁶ At 3 months, the percentage of basophils (although not its count) increased slightly, while platelets decreased in both implanted and control rabbits. At 6 months, implanted rabbits showed slight eosinophilia but no statistically significant differences from the control group.

Postmortem Macroscopic Assessment. External exams during the necropsy study did not reveal any abnormality signs in any animal. No noticeable differences were observed between the implanted groups and blank controls either. Internal exams of organs and spinal tissues did not reveal any abnormality or inflammatory signs in any animal. Again, we observed no noticeable differences between the implanted groups and blank controls.

External animal exams and internal organ and spinal tissue examinations showed no abnormalities, inflammatory changes, or noticeable differences between treatments (particle implantation and control groups) or survival periods (3 and 6 months). In addition, we found no signs of toxicity reactions to Bionate 80A particles implanted in the New Zealand rabbit L₆ epidural space.

Histological Analysis of Organs and Tissues. We found no inflammatory reaction in the control rabbits 3 or 6 months after surgery.

Analysis of the drained lymph nodes and organs from the rabbits revealed no microscopic changes or Bionate particles in any rabbit, neither at 3 nor 6 months. In addition, the Bionate particles did not migrate from their original location, next to the spinal cord, and we found no inflammatory reaction. The slices we analyzed were two for the kidneys (one from the right and one from the left), two for the liver (including the gallbladder),

and one for the spleen. In all cases, we used midsections of the organs. Concerning the analysis of the spinal cord and its adjacent tissues, we identified macroscopically the zone where we implanted the particles based on the apparent lack of vertebral lamina due to the hemilaminectomy we performed in the surgery.

We located the Bionate particles and identified an associated inflammatory reaction in all implanted rabbits, finding a chronic granulomatous inflammatory response with giant multinucleated cells. This response is the expected reaction to foreign bodies, such as the Bionate particles. At 400× per field, we saw an average of 17 ± 5.22 SD giant cells containing the particles at 3 months and 25 ± 7.63 SD cells at 6 months, thus showing their phagocytosis. We identified no acute inflammatory reaction in any of the cases. The chronic inflammatory response affected only the soft tissues (mainly muscle) surrounding the spinal cord. Furthermore, the reaction always happened outside the *dura mater* (Figure 5).

Under microscopic examination, the Bionate 80A particles recovered from the implantation side had not changed and looked like those that were not implanted.

DISCUSSION

Bionate 80A shows excellent *in vitro* resistance to oxidative challenge,^{19,37,38} hydrolytic tests,¹⁸ cholesterol esterase enzymes,^{39,40} and wear and tear,¹¹ better than other polymeric^{14,38,41} or metallic materials.⁹ Also, *in vitro*, it performs well under good hydration, and long-term cracks grow very slowly.²² Moreover, it has no L929 fibroblast cell *in vitro* cytotoxicity, with good cell cytocompatibility and adherence.¹⁶

In vitro as an acetabular replacement in partial hip joint arthroplasty shows an excellent performance with minimal wear and tear⁴² but moderate femoral head cartilage volume loss.⁴³ Thus, its properties, especially when hydrated, are the closest to the articular cartilage but not quite the same.²²

In vivo, Bionate 80A showed excellent results in the acetabular sheep replacement with no signs of material degradation, local wear particle release, lymph node, or distant organ migration.²⁰ The results of our study corroborate it.

While the original Bionate 80A is colorless, the gamma sterilized implants have a yellowish color, attesting that although minimal, this sterilization method induces some deleterious effects¹² (*i.e.*, 9% reduction in its mechanical resistance²³). For our study, this has no meaning, but it might play a role in long-term discal replacements or dynamic spinal fusions. It is an area that needs further evaluation.

In vivo, long-term reaction data are limited and come from live patient device explants. The only study on explanted Bryan

cervical disc prosthesis¹⁵ describes a minimal periprosthetic inflammatory reaction with polymeric debris globular in shape and 3.89 μm in diameter. However, the response elicited could not be separated from the one induced by the metallic wear and tear titanium particles. Meanwhile, several studies deal with explanted lumbar Dynesis dynamic stabilization devices. All have shown minimal wear,³⁹ rubbing surface burnishing,^{12,39,44} and small cracks^{12,13,39} in the exposed surfaces^{13,39} not deeper than 10 μm ,¹² so the effect was negligible. The particle size was >10 μm and in no case under 0.46 μm ⁴⁴ (the most inflammatory inductive particles⁴⁵). Local tissue reaction was limited to macrophage proliferation and fibroblastic capsular formation but no chronic inflammatory response or wear debris.⁴⁴ These changes persist unchanged even after 7 years.¹³ Unfortunately, as already happened with the Bryan cervical disc, it is not easy to separate the reaction induced by the implant's Bionate 80A, polyethylene-terephthalate cord, and titanium alloy.^{12,44}

In vivo, there are published studies on epidural foreign particle implantation in rabbits with PEEK,^{46,47} stainless steel,⁴⁸ cobalt–chromium,^{48,49} nitinol,⁹ titanium,^{9,48} UHMWP,⁴⁸ ceramic,⁴⁸ polytetrafluorethylene,⁴⁸ silicone,⁴⁸ polyethene terephthalate,⁴⁸ polyester,⁴⁸ polyether ketone,⁴⁸ and a non-specified polycarbonate urethane.⁴⁸ Animals were euthanized at 3 and 6 months after follow-up. There was epidural fibrosis in all of them but intradural particle diffusion only in the metallic groups, with additional intradural fibrosis. Epidural cobalt oxide implantation in the rat induced chronic deafferentation pain,⁵⁰ an event not described in any of the studies mentioned above, perhaps because it is a different chemical agent or research animal. There was no intrathecal particle penetration in polymeric implants, and the spinal cord, subdural space, and nerve roots did not develop any inflammatory response. No group showed a reticuloendothelial or systemic reaction. Our study confirms that the Bionate 80A does not penetrate the *dura mater* or migrate to regional lymph nodes or distant organs. Our hematological and urine periodical tests data rule out acute or toxic Bionate 80A responses.

A future line of investigation is the analysis of the possible degradation products generated as a consequence of the long-term use and deterioration of this material (“Extractables and Leachables” according to ISO 10993) as reported by other research groups,²⁷ as well as the evaluation of the possible biological effects of these resulting products of degradation.

LIMITATIONS

The number of animals is small, and the postoperative follow-up is short. A more considerable number of animals would supply more reliable statistical values, and a more prolonged rabbit survival would show its long-term effects. Furthermore, in the clinical setting, the wear particles are liberated continuously and not in a highly concentrated dose as used in the present study.

STRENGTHS

We have done behavioral, hematological, urinary, macroscopic, and microscopic studies for each animal, including draining lymph nodes and distant organs. We have also studied the local peri-implant tissues and, most importantly, the intradural responses induced by Bionate 80A particles.

CONCLUSIONS

According to the results obtained with clinical behavioral parameters, blood and urine tests, necropsy, and histopatho-

logical studies, the Bionate particles, when implanted in the rabbit lumbar epidural space, do not generate a significant immunological reaction limited to the soft tissues surrounding the implanted particles, with giant multinucleated cells typical of responses against a foreign body. In addition, the particles did not migrate from the original implantation site to draining lymph nodes or inner organs or cross the *dura mater*. Thus, we consider that the Bionate wear particles effect is not severe enough to recommend against using this material in spinal implants.

AUTHOR INFORMATION

Corresponding Author

Vicente Vanaclocha – University of Valencia, Valencia 46015, Spain; orcid.org/0000-0002-4909-5886; Phone: +34 669 79 00 13; Email: vivava@uv.es; Fax: 34 96 340 99 22

Authors

Amparo Vanaclocha-Saiz – Instituto de Biomecánica (IBV), Universitat Politècnica de Valencia, Valencia 46022, Spain
Carlos Atienza – Instituto de Biomecánica (IBV), Universitat Politècnica de Valencia, Valencia 46022, Spain
Pablo Jorda-Gomez – Hospital General Universitario de Castellón, Castellón de la Plana 12004, Spain
Víctor Primo-Capella – Instituto de Biomecánica (IBV), Universitat Politècnica de Valencia, Valencia 46022, Spain
Carlos Barrios – Catholic University of Valencia, Valencia 46001, Spain
Leyre Vanaclocha – Medius Klinik, Ostfildern-Ruit Klinik für Urologie, 73760 Ostfildern, Germany

Complete contact information is available at:
<https://pubs.acs.org/10.1021/acsomega.2c01690>

Funding

None of the authors had any funding for this study.

Notes

The authors declare no competing financial interest.

ACKNOWLEDGMENTS

We thank Amelia Gómez for assistance and help.

REFERENCES

- (1) Bian, Y.-Y.; Zhou, L.; Zhou, G.; Jin, Z.-M.; Xin, S.-X.; Hua, Z.-K.; Weng, X.-S. Study on Biocompatibility, Tribological Property and Wear Debris Characterization of Ultra-Low-Wear Polyethylene as Artificial Joint Materials. *J. Mech. Behav. Biomed. Mater.* **2018**, *82*, 87–94.
- (2) Chappard, D.; Rony, L.; Ducellier, F.; Steiger, V.; Hubert, L. Wear Debris Released by Hip Prosthesis Analysed by Microcomputed Tomography. *J. Microsc.* **2021**, *282*, 13–20.
- (3) Goodman, S. B.; Gallo, J. Periprosthetic Osteolysis: Mechanisms, Prevention and Treatment. *J. Clin. Med.* **2019**, *8*, 2091.
- (4) Cordova, L. A.; Stresing, V.; Gobin, B.; Rosset, P.; Passuti, N.; Gouin, F.; Trichet, V.; Layrolle, P.; Heymann, D. Orthopaedic Implant Failure: Aseptic Implant Loosening—the Contribution and Future Challenges of Mouse Models in Translational Research. *Clin. Sci. (Lond)* **2014**, *127*, 277–293.
- (5) Urban, R. M.; Jacobs, J. J.; Tomlinson, M. J.; Gavrilovic, J.; Black, J.; Peoc'h, M. Dissemination of Wear Particles to the Liver, Spleen, and Abdominal Lymph Nodes of Patients with Hip or Knee Replacement. *J. Bone Joint Surg. Am.* **2000**, *82*, 457–477.
- (6) Urban, R. M.; Tomlinson, M. J.; Hall, D. J.; Jacobs, J. J. Accumulation in Liver and Spleen of Metal Particles Generated at Nonbearing Surfaces in Hip Arthroplasty. *J. Arthroplasty* **2004**, *19*, 94–101.

- (7) Green, T. R.; Fisher, J.; Stone, M.; Wroblewski, B. M.; Ingham, E. Polyethylene Particles of a "critical Size" Are Necessary for the Induction of Cytokines by Macrophages in Vitro. *Biomaterials* **1998**, *19*, 2297–2302.
- (8) Werner, J. H.; Rosenberg, J. H.; Keeley, K. L.; Agrawal, D. K. Immunobiology of Periprosthetic Inflammation and Pain Following Ultra-High-Molecular-Weight-Polyethylene Wear Debris in the Lumbar Spine. *Expert Rev. Clin. Immunol.* **2018**, *14*, 695–706.
- (9) Rhalmi, S.; Charette, S.; Assad, M.; Coillard, C.; Rivard, C. H. The Spinal Cord Dura Mater Reaction to Nitinol and Titanium Alloy Particles: A 1-Year Study in Rabbits. *Eur. Spine J.* **2007**, *16*, 1063–1072.
- (10) La Budde, J. K.; Orosz, J. F.; Bonfiglio, T. A.; Pellegrini, V. D., Jr. Particulate Titanium and Cobalt-Chrome Metallic Debris in Failed Total Knee Arthroplasty. A Quantitative Histologic Analysis. *J. Arthroplasty* **1994**, *9*, 291–304.
- (11) Elsner, J. J.; Mezape, Y.; Hakshur, K.; Shemesh, M.; Linder-Ganz, E.; Shterling, A.; Eliaz, N. Wear Rate Evaluation of a Novel Polycarbonate-Urethane Cushion Form Bearing for Artificial Hip Joints. *Acta Biomater.* **2010**, *6*, 4698–4707.
- (12) Cipriani, E.; Bracco, P.; Kurtz, S. M.; Costa, L.; Zanetti, M. In-Vivo Degradation of Poly(Carbonate-Urethane) Based Spine Implants. *Polym. Degrad. Stab.* **2013**, *98*, 1225–1235.
- (13) Ianuzzi, A.; Kurtz, S. M.; Kane, W.; Shah, P.; Siskey, R.; van Ooij, A.; Bindal, R.; Ross, R.; Lanman, T.; Büttner-Jan, K.; Isaza, J. In Vivo Deformation, Surface Damage, and Biostability of Retrieved Dynesys Systems. *Spine (Phila Pa 1976)* **2010**, *35*, E1310–E1316.
- (14) Smith, R. A.; Hallab, N. J. In Vitro Macrophage Response to Polyethylene and Polycarbonate-Urethane Particles. *J. Biomed. Mater. Res., Part A* **2010**, *93*, 347–355.
- (15) Anderson, P. A.; Rouleau, J. P.; Toth, J. M.; Riew, K. D. A Comparison of Simulator-Tested and -Retrieved Cervical Disc Prostheses. Invited Submission from the Joint Section Meeting on Disorders of the Spine and Peripheral Nerves, March 2004. *J. Neurosurg.: Spine* **2004**, *1*, 202–210.
- (16) Arjun, G. N.; Ramesh, P. Structural Characterization, Mechanical Properties, and in Vitro Cytocompatibility Evaluation of Fibrous Polycarbonate Urethane Membranes for Biomedical Applications. *J. Biomed. Mater. Res., Part A* **2012**, *100A*, 3042–3050.
- (17) Khan, I.; Smith, N.; Jones, E.; Finch, D. S.; Cameron, R. E. Analysis and Evaluation of a Biomedical Polycarbonate Urethane Tested in an in Vitro Study and an Ovine Arthroplasty Model. Part I: Materials Selection and Evaluation. *Biomaterials* **2005**, *26*, 621–631.
- (18) Mishra, A.; Seethamraju, K.; Delaney, J.; Willoughby, P.; Faust, R. Long-Term in Vitro Hydrolytic Stability of Thermoplastic Polyurethanes. *J. Biomed. Mater. Res., Part A* **2015**, *103*, 3798–3806.
- (19) Dempsey, D. K.; Carranza, C.; Chawla, C. P.; Gray, P.; Eoh, J. H.; Cereceres, S.; Cosgriff-Hernandez, E. M. Comparative Analysis of in Vitro Oxidative Degradation of Poly(Carbonate Urethanes) for Biostability Screening. *J. Biomed. Mater. Res., Part A* **2014**, *102*, 3649–3665.
- (20) Khan, I.; Smith, N.; Jones, E.; Finch, D. S.; Cameron, R. E. Analysis and Evaluation of a Biomedical Polycarbonate Urethane Tested in an in Vitro Study and an Ovine Arthroplasty Model. Part II: In Vivo Investigation. *Biomaterials* **2005**, *26*, 633–643.
- (21) Kanca, Y.; Milner, P.; Dini, D.; Amis, A. A. Tribological Evaluation of Biomedical Polycarbonate Urethanes against Articular Cartilage. *J. Mech. Behav. Biomed. Mater.* **2018**, *82*, 394–402.
- (22) Ford, A. C.; Gramling, H.; Li, S. C.; Sov, J. V.; Srinivasan, A.; Pruitt, L. A. Micromechanisms of Fatigue Crack Growth in Polycarbonate Polyurethane: Time Dependent and Hydration Effects. *J. Mech. Behav. Biomed. Mater.* **2018**, *79*, 324–331.
- (23) Kurtz, S. M.; Siskey, R.; Reitman, M. Accelerated Aging, Natural Aging, and Small Punch Testing of Gamma-Air Sterilized Polycarbonate Urethane Acetabular Components. *J. Biomed. Mater. Res., Part B* **2010**, *93B*, 442–447.
- (24) Dempsey, D. J.; Thirucote, R. R. Sterilization of Medical Devices: A Review. *J. Biomater. Appl.* **1988**, *3*, 454–523.
- (25) Lopianiak, I.; Butruk-Raszeja, B. A. Evaluation of Sterilization/Disinfection Methods of Fibrous Polyurethane Scaffolds Designed for Tissue Engineering Applications. *Int. J. Mol. Sci.* **2020**, *21*, 8092.
- (26) Harrell, C. R.; Djonov, V.; Fellabaum, C.; Volarevic, V. Risks of Using Sterilization by Gamma Radiation: The Other Side of the Coin. *Int. J. Med. Sci.* **2018**, *15*, 274–279.
- (27) Shintani, H. Formation and Elution of Toxic Compounds from γ -Ray-Sterilized Medical Products and the Ames Test of Eluted Components. *Biocontrol Sci.* **2015**, *20*, 135–145.
- (28) Vanaclocha-Saiz, A.; Vanaclocha, V.; Atienza, C. M.; Clavel, P.; Jorda-Gomez, P.; Barrios, C.; Vanaclocha, L. Finite Element Analysis of a Bionate Ring-Shaped Customized Lumbar Disc Nucleus Prosthesis. *ACS Appl. Bio Mater.* **2022**, *5*, 172–182.
- (29) 14:00–17:00. ISO 10993-6:2007 *Biological evaluation of medical devices — Part 6: Tests for local effects after implantation*; <https://www.iso.org/cms/render/live/en/sites/isoorg/contents/data/standard/04/47/44789.html> (accessed 2022–01–06).
- (30) 14:00–17:00. ISO 10993-11:2006 <https://www.iso.org/cms/render/live/en/sites/isoorg/contents/data/standard/03/59/35977.html> (accessed 2022–01–06).
- (31) *Standard Practice for Short-Term Screening of Implant Materials*; <https://www.astm.org/f0763-04.html> (accessed 2022–01–06).
- (32) Ministerio de la Presidencia *Real Decreto 1201/2005, de 10 de Octubre, Sobre Protección de Los Animales Utilizados Para Experimentación y Otros Fines Científicos*; 2005; Vol. BOE-A-2005-17344, pp 34367–34391.
- (33) *Standard Practice for Evaluating Acute Systemic Toxicity of Material Extracts by Systemic Injection in the Mouse*; <https://www.astm.org/f0750-20.html> (accessed 2022–01–06).
- (34) *Standard Practice for Extraction of Materials Used in Medical Devices*; <https://www.astm.org/f0619-20.html> (accessed 2022–01–06).
- (35) *Standard Practice for Testing the Biological Responses to Particles in vivo*; <https://www.astm.org/f1904-14.html> (accessed 2022–01–06).
- (36) Stancu, C. A.; Cărpinișan, L.; Ghișe, A.; Marcu, A.; Pentea, M. C.; Dumitrescu, E.; Muselin, F.; Militaru, D.; Cristina, T. R. Clinical Chemistry, Haematology, Immune Response and Histological Evaluation of Rabbits after Immunisation and Challenge with Rabbit Haemorrhagic Disease (RDH) Virus. *World Rabbit Sci.* **2017**, *25*, 357–365.
- (37) Lawless, B. M.; Espino, D. M.; Shepherd, D. E. T. In Vitro Oxidative Degradation of a Spinal Posterior Dynamic Stabilization Device. *J. Biomed. Mater. Res., Part B* **2018**, *106*, 1237–1244.
- (38) Chandy, T.; Van Hee, J.; Nettekoven, W.; Johnson, J. Long-Term in Vitro Stability Assessment of Polycarbonate Urethane Micro Catheters: Resistance to Oxidation and Stress Cracking. *J. Biomed. Mater. Res., Part B* **2009**, *89B*, 314–324.
- (39) Shen, M.; Zhang, K.; Koettig, P.; Welch, W. C.; Dawson, J. M. In Vivo Biostability of Polymeric Spine Implants: Retrieval Analyses from a United States Investigational Device Exemption Study. *Eur. Spine J.* **2011**, *20*, 1837–1849.
- (40) Christenson, E. M.; Patel, S.; Anderson, J. M.; Hiltner, A. Enzymatic Degradation of Poly(Ether Urethane) and Poly(Carbonate Urethane) by Cholesterol Esterase. *Biomaterials* **2006**, *27*, 3920–3926.
- (41) Christenson, E. M.; Dadsetan, M.; Wiggins, M.; Anderson, J. M.; Hiltner, A. Poly(Carbonate Urethane) and Poly(Ether Urethane) Biodegradation: In Vivo Studies. *J. Biomed. Mater. Res., Part A* **2004**, *69A*, 407–416.
- (42) Scholes, S. C.; Burgess, I. C.; Marsden, H. R.; Unsworth, A.; Jones, E.; Smith, N. Compliant Layer Acetabular Cups: Friction Testing of a Range of Materials and Designs for a New Generation of Prosthesis That Mimics the Natural Joint. *Proc. Inst. Mech. Eng., Part H* **2006**, *220*, 583–596.
- (43) Hernigou, P.; Quiennec, S.; Guissou, I. Hip Hemiarthroplasty: From Venable and Bohlman to Moore and Thompson. *Int. Orthop.* **2014**, *38*, 655–661.
- (44) Neukamp, M.; Roeder, C.; Veruva, S. Y.; MacDonald, D. W.; Kurtz, S. M.; Steinbeck, M. J. In Vivo Compatibility of Dynesys(®) Spinal Implants: A Case Series of Five Retrieved Periprosthetic Tissue

Samples and Corresponding Implants. *Eur. Spine J.* **2015**, *24*, 1074–1084.

(45) Ingham, E.; Fisher, J. Biological Reactions to Wear Debris in Total Joint Replacement. *Proc. Inst. Mech. Eng., Part H* **2000**, *214*, 21–37.

(46) Hallab, N. J.; Bao, Q.-B.; Brown, T. Assessment of Epidural versus Intradiscal Biocompatibility of PEEK Implant Debris: An in Vivo Rabbit Model. *Eur. Spine J.* **2013**, *22*, 2740–2751.

(47) Rivard, C.-H.; Rhalmi, S.; Coillard, C. In Vivo Biocompatibility Testing of Peek Polymer for a Spinal Implant System: A Study in Rabbits. *J. Biomed. Mater. Res.* **2002**, *62*, 488–498.

(48) Cunningham, B. W.; Hallab, N. J.; Hu, N.; McAfee, P. C. Epidural Application of Spinal Instrumentation Particulate Wear Debris: A Comprehensive Evaluation of Neurotoxicity Using an in Vivo Animal Model. *J. Neurosurg.: Spine* **2013**, *19*, 336–350.

(49) Hallab, N. J.; Chan, F. W.; Harper, M. L. Quantifying Subtle but Persistent Peri-Spine Inflammation in Vivo to Submicron Cobalt-Chromium Alloy Particles. *Eur. Spine J.* **2012**, *21*, 2649–2658.

(50) Vanaclocha, V.; Saiz-Sapena, N. Modelo de Dolor Crónico Por Deaferentización En La Rata Mediante Óxido de Cobalto. *Dolor* **1991**, *6*, 68–71.