

SHORT COMMUNICATION: MASSIVE MORTALITY IN RABBITS BY MADURAMICIN POISONING

Martino P.E.^{*}, Parrado E.[†], Sanguinetti R.[‡], Espinoza C.[‡], Debenedetti R.[†], Di Benedetto N.M.[†],
Cisterna C.[‡], Gómez P.[†]

^{*}Pathology and Microbiology Department, CIC, Veterinary College, CC 296 (1900), LA PLATA, Argentina.

[†]Toxicology Laboratory, Chemistry and Pathology, SENASA, National Animal Health Service, Av. Fleming 1653,
Martínez, BUENOS AIRES, Argentina.

[‡]CIC-CCV and A-INTA, CC 77, 1708 Morón, BUENOS AIRES, Argentina.

ABSTRACT: A spontaneous outbreak of maduramicin intoxication in domestic rabbits (*Oryctolagus cuniculus*) is reported. It is believed that maduramicin incorporated as a coccidiostat into poultry pellet fed to rabbits was the cause, as up to 2.01 ppm was found in the samples and cardiopulmonary clinical signs in most of the rabbits was the common pattern. Findings here were consistent with the classic indications observed in ionophore toxicosis in different species, but little is known about the toxicity of maduramicin in rabbits.

Key Words: maduramicin, ionophore toxicosis, rabbit.

INTRODUCTION

Maduramicin is one of the most widely used polyether ionophore antibiotics and has been recommended both as anticoccidial additive for broilers and as a growth promoting feed additive for cattle (Novilla, 1992). On the other hand, it is considered the most toxic of all the ionophores, and intoxication syndromes can easily result from overdosage and misuse (Oehme and Pickrell, 1999). Maduramicin toxicity has been recorded in a variety of species including humans (Sharma *et al.*, 2005), but there is a lack of information regarding its deleterious effects on rabbits. This paper reports an acute maduramicin intoxication in 44 commercial rabbit farms of Buenos Aires province, where rabbits were fed a commercial balanced pellet from a poultry feed manufacturer.

MATERIAL AND METHODS

A clinical examination was carried out on the affected rabbits, and serum biochemical and haematologic variables were measured from the peripheral blood. There were also serological tests (ELISA and HIA for Viral Rabbit Haemorrhagic Disease, RHD).

Blood reference values were taken into consideration in accordance with the literature (Uko *et al.*, 2000; Weschler, 1983).

A complete necropsy was performed, and samples were taken for routine histology and bacteriology. Pellets were examined for the presence of organochlorine and organophosphate pesticides, pyrethroids, mycotoxins and ionophores (maduramicin, narasin, lasalocid, monensin and salinomycin) as described by Hamilton *et al.*, 1981 and De Jong *et al.*, 2004. Chromatographic analysis for ionophores was carried out on a LC-10AVP Shimadzu High Performance Liquid Chromatograph. Cyanide and heavy metal (As, Pb, Hg, Cd) residues were also investigated with a Perkin-Elmer Model 5100 Atomic Absorption Spectrophotometer equipped with a Zeeman 5000 Z1 Furnace.

RESULTS AND DISCUSSION

The incident occurred on 2 December, 2005 with an overall toll of approximately 20,000 deaths (mortality reached 100% in some farms). The affected animals were New Zealand White×Californian crossing of both sexes and of all ages. Clinically, the first indications were lethargy followed by an increased heart rate with marked dyspnoea and death after 4 or 5 d from the initial feeding. Animals remained afebrile and, in some instances, reproductive problems were seen. On December 24, the pellet feed was replaced, deaths become restricted to the already clinically advanced cases and no new cases appeared. Haematologic parameters such as mean haemoglobin concentration (< 11.2 g/dL), total red blood cells count ($< 4.49 \times 10^{12}/L$), packed cell volume ($< 38\%$) and calcium level (0.9-1.9 mmol/L) were reduced, while urea (6.4-7.2 mmol/L), phosphorus (7.2-9.9 mmol/L), and the activities of aspartate transaminase (AST, 42.3-8.84 UI/L) and creatine phosphokinase (CPK, 2870-4990 U/L) were elevated. *Post mortem* examination revealed generalised signs of congestive cardiac failure. The heart was enlarged, with widespread myocardial haemorrhages, while other major organs were congestive and swollen (Figure 1). Histologically, a general picture of hyperaemia, haemorrhage and oedema were noted, especially in the major organs. In particular, focal myodegeneration and necrosis were present in cardiac muscle (Figure 2), and the severity of lesions varied between individual rabbits perhaps in relation to the quantity ingested or the individual susceptibility (Salles *et al.*, 1994). Moderate signs or no signs of degeneration at any stage were visible in the skeletal muscles examined. Analysis by high performance liquid chromatography revealed that the pellet specimens consistently contained between 1.78 and 2.01 ppm of maduramicin. The rest of the compounds were absent or were present only in trace amounts (e.g., mercury was detected

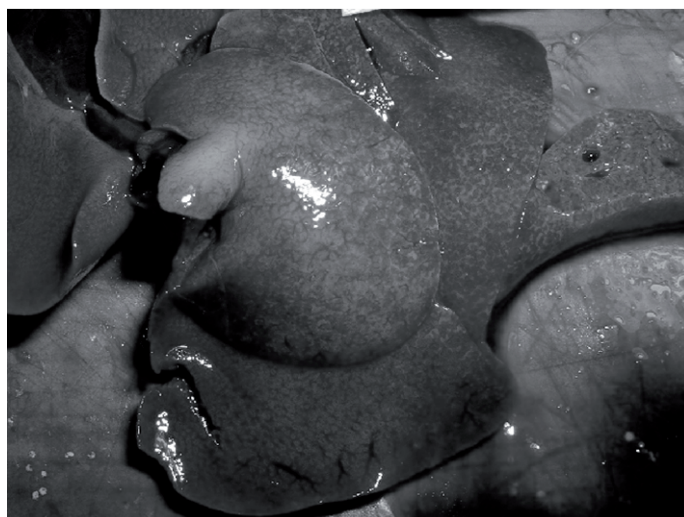

Figure 1: Liver. Hepatomegaly and haemorrhage on the surface.




Figure 2: Myocardium. Myocyte hyalinization and necrosis. Haematoxylin and eosin, $\times 200$.

at very low levels: $0.01 \mu\text{g/g}$), except for the mycotoxin DON (vomitoxin) found at moderate levels (3,500 ppb) in a few specimens. RHD was initially suspected, but serological investigation was negative and indeed the country remains free from the disease (Martino *et al.*, 2000). Maduramicin has been studied in the experimental control of rabbit coccidiosis at 1.5 ppm by Polozowsky (1993), but this author only mentions toxicity of the ionophore for rabbits at a dosage of 4.5 ppm. Except for the confirmation that maduramicin could be toxic for rabbit with less than 2 ppm in the feed (Licois, personal communication), poisoning in this animal due to feeding of toxic doses of this ionophore has not been reported so far. Salles *et al.* (1994) reports a 15% mortality on rabbit farms by narasin intoxication, with clinical and morphological characteristics similar to those detailed here. In addition, our findings resemble closely those described as typical of congestive heart failure by any kind of ionophore poisoning in various species (Bastianello *et al.*, 1995; Schlosberg *et al.*, 1997). A possible microcytic anaemia was seen, but the most important indices were the increased levels of AST and CPK (CPK activities in individual animals peaked at 4990 U/L), suggesting principally cardiac muscle damage. Myocardial lesions predominated over skeletal muscle lesions in this survey. In different species, the clinical expressions may be in cardiac or skeletal muscle, or in both (Oehme and Pickrell, 1999). As the percentage of rabbit feed is very low in bulk compared to the rest of animal feeds, there is a fair possibility that rabbit feed will be contaminated with constituents of batches previously prepared for other animals (Arts, 1991). Factors determining the occurrence of ionophore toxicity include overdosage, as well as misuse like administration to non-target animal species (Novilla, 1992). On the other hand, an obvious synergistic effect may have occurred in those cases where DON was detected.

CONCLUSION

The main conclusion from this episode is that the inadvertent feeding of maduramicin-medicated poultry feed to rabbits may cause severe poisoning.

Acknowledgement: This study was partially supported by grants from CIC (Provincial Scientific Research Council), and SENASA (Argentina).

REFERENCES

- Arts, H.T. 1991. Poisoning due to an ionophore anticoccidial agent in a commercial rabbit breeding farm. *Tijdschr. Diergeneeskd.* 116: 504-507.
- Bastianello S.S., Fourie N., Prozesky L., Nel P. 1995. Cardiomyopathy of ruminants induced by the litter of poultry fed on rations containing the ionophore antibiotic, maduramicin. *Onderstepoort J. Vet. Res.*, 62: 5-18.
- De Jong J. B., Stoisser K., Wagner M., Tomassen J., Driessen J., Hofmann P., Putzka H. 2004. Determination of maduramicin in feedingstuffs and premixtures by liquid chromatography. *JAOAC Int.*, 87: 1033-1041.
- Hamilton G.A., Rutven A.D., Findlay E., Hunter K., Lidsay D. 1981. Wildlife deaths resulting from misuse of agricultural chemicals. *Biol. Conserv.*, 21: 315-326.
- Martino P.E., Samus S., Piscopo M., Risso M., Lacchini R. 2000. Randomised sanitary status of Argentinean rabbitry. *World Rabbit Sci.*, 8: 145-147.
- Novilla M.N. 1992. The veterinary importance of the toxic syndrome induced by ionophores. *Vet. Hum.Toxicol.*, 34: 66-70.
- Oehme F.W., Pickrell J.A. 1999. An analysis of the chronic oral toxicity of polyether ionophore antibiotics in animals. *Vet. Hum. Toxicol.*, 41: 251-257.
- Polozowski A. 1993. Coccidiosis of rabbits. *Wiad. Parazytol.*, 39: 13-28.
- Salles M.S., Lombardo de Barros C.S., Barros S. 1994. Ionophore antibiotic (narasin) poisoning in rabbits. *Vet. Hum. Toxicol.* 36: 437-444.
- Shlosberg A., Perl S., Harmelin A., Hanji V., Bellaiche M. 1997. Acute maduramicin toxicity in calves. *Vet. Rec.* 140: 643-646.
- Sharma N., Bhalla A., Varma S., Jain S., Singh S. 2005. Toxicity of maduramicin. *Emerg. Med. J.* 22: 880-882.
- Uko O.J., Ataja A.M., Tanko H.B. 2000. Weight gain, haematology and blood chemistry of rabbits fed cereal offals. *Sokoto J. Vet. Sci.*, 2: 18-26.
- Weschler N.B. 1983. Blood collection techniques and normal values for ferrets, rabbits, and rodents: a review. *Vet. Med. N.Am./Small Anim. Clin.* 78: 713-713.
-