

NON INVASIVE METHOD TO STUDY THE BODY COMPOSITION OF RABBITS BY X-RAY COMPUTERISED TOMOGRAPHY

ROMVARI R.*, MILISITS G.*, SZENDRO ZS.*, SØRENSEN P.**

* PANNON Agricultural University, Faculty of Animal Sciences, H-7400 KAPOSVAR, P.O. Box 16, Hungary -

** National Institute of Animal Sciences, Foulum, 8830 TJELE, Denmark

ABSTRACT : X-ray computerised tomography (CT) techniques for non-invasive and exact study of rabbit body composition are reviewed. The method is fairly accurate in determining total body fat and energy content ($R^2=0.8-0.9$), but less so in predicting total body protein content ($R^2=0.4-0.7$). It may be also applied for the *in vivo* quantitation of valuable meat parts due to correlations (≈ 0.7) between main carcass traits and CT data. The rather high cost of examination may be reduced by scanning three rabbits

simultaneously, which corresponds 12 to 36 animals per hour. This reduced cost is comparable to that of the whole body chemical analysis or of the progeny test and, unlike the latter, the CT method does not increase the generation interval during selection. Different scanning and evaluating technics may be applied in the selection programs for estimation of carcass traits, for improving the dressing percentage and to follow the development of important tissues in the same rabbit during the whole growing period.

RESUME : Les techniques de tomographie à compteur de rayons X (CT) utilisées pour une étude exacte et non invasive de la composition corporelle du lapin sont passées en revue. Cette méthode est parfaitement précise pour prédire la quantité totale de graisse corporelle et le contenu énergétique ($R^2 = 0.8-0.9$) mais l'est beaucoup moins pour prédire le contenu total en protéines corporelles ($R^2 = 0.4-0.7$). Elle peut aussi être appliquée à l'évaluation *in vivo* des meilleures parties de la carcasse grâce à la corrélation (≈ 0.7) entre les principales caractéristiques de la carcasse et les résultats de la CT. Le coût relativement élevé de la

technique peut être réduit en scannant trois lapins simultanément, ce qui correspond à 12 à 36 animaux examinés par heure. Ce coût réduit est comparable à celui de l'analyse chimique de toute la carcasse ou du test sur la descendance et, contrairement à ce dernier, la méthode CT n'augmente pas l'intervalle entre les générations pendant la sélection. Différentes techniques de scanner et d'évaluation peuvent être appliquées dans des programmes de sélection pour évaluer les caractéristiques de la carcasse, améliorer le rendement à l'abattage et suivre le développement des tissus importants sur le même lapin durant toute sa période de croissance.

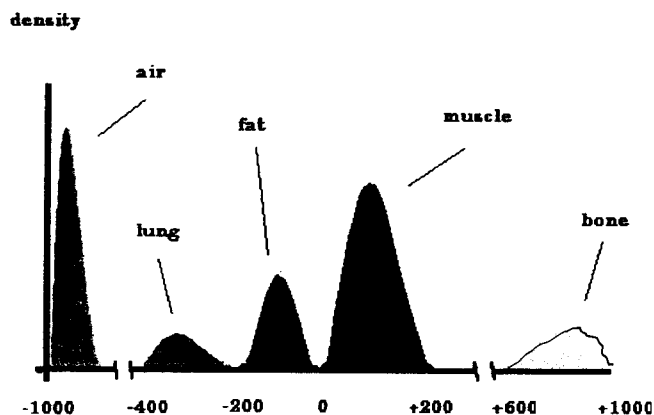
INTRODUCTION

The X-ray computerised tomography (CT) is suitable for the individual examination of tissues in different depths. On the so-called Hounsfield scale the different tissues can be separated according to their X-ray densities. (HOUNSFIELD, 1980). The whole scale ranges from -1000 (no absorption) to +1000 Hounsfield units (HU) (total absorption), definitively the 0 point is the density value of water (Fig. 1.).

During the 1980s Norwegian scientists showed that the different tissues of domestic animals can be characterised by non-overriding HU value intervals (SKJERVOLD *et al.*, 1981). In this scale the fat tissue ranges between about -200 and -20 and the muscle between about +20 and +200 HU.

The objective of this paper is to give a short review of CT scanning in rabbit research.

Figure 1 : The Hounsfield scale



PICTURE FORMATION

In the Pannon Agricultural University the CT Biological Centre started working in 1990 with a Siemens Somatom DRG type, third generation CT scanner (HORN, 1991). At present the digital imaging centre has a newer, so-called spiral CT and a NMR instrument, too, which are used both in medical diagnostic and animal science.

Fig. 2. shows the traditional way of picture forming. The experimental object to be examined consists of nine cubes with numbers showing their X-ray density values. As it can be seen, the summarised density values of the levels are the same on the X-ray film.

It means that this type of picture forming represents the summation of the density values of different layers on the same X-ray film. The computerised tomography can eliminate this problem.

Figure 2 : Base of the two dimensional picture forming

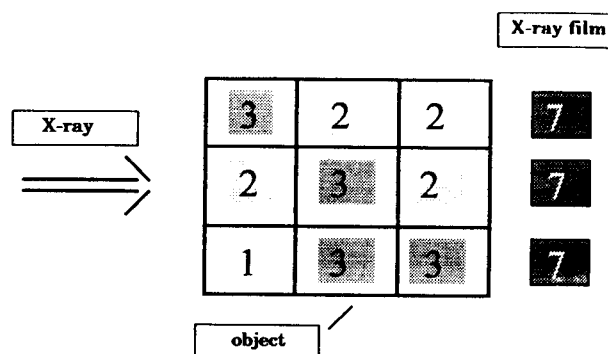


Figure 3 : The X-ray tube and the detector field

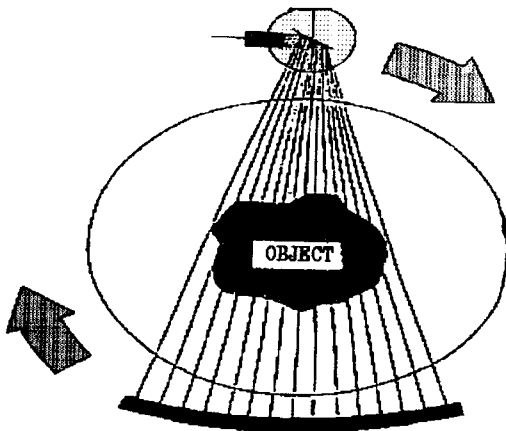
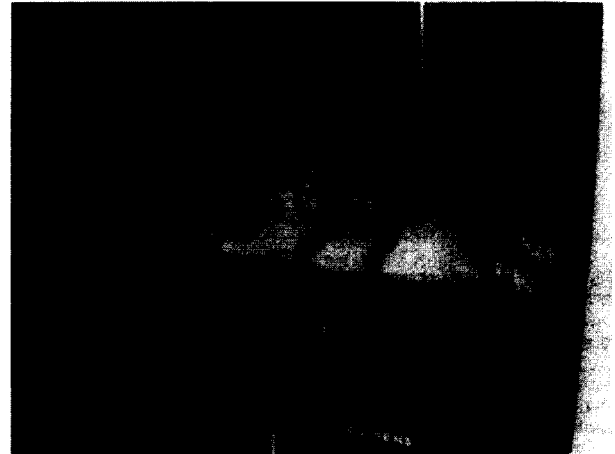

Fig. 3. shows the operation principle of a CT scanner. The X-ray tube and, on the opposite side, the detector field make a full rotation around the object during the scanning process. At an optionally chosen degree of rotation a 1 to 2 ms X-ray pulse is given. E.g. 360 pulses multiplied by 512 detectors give 184320 observations of X-ray absorption. Then the computer combines these observations with the 360 rotational positions and forms a single tomogram (scan, CT picture) on a matrix composed of 256 x 256 elements. (It differs from the topogram which is an overview of the object). Each point of the matrix (called pixel) represents a

Figure 4 : Fixed rabbit in the special container



density value expressed in HU units.

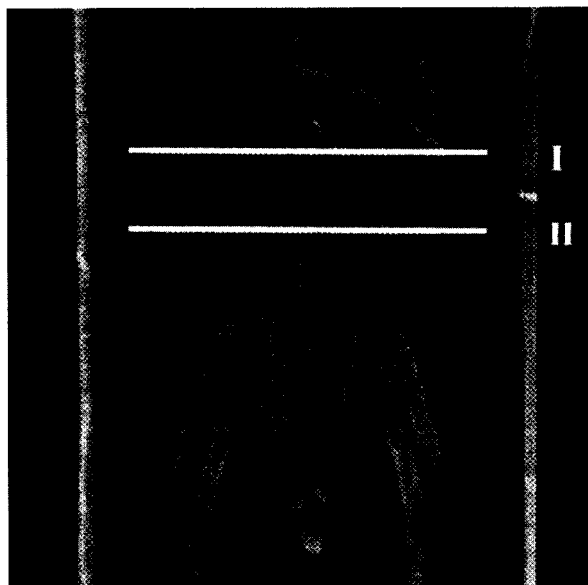
We used to take the CT pictures after eight hours fast, because the filled gastrointestinal tract deteriorates picture quality. The rabbits are fixed with belts on stretch position, lying flat in special plexiglass containers during examination without using anaesthetics (*Fig. 4.*). In this situation the animals cannot move and the legs are well separated from the body. For pregnant does anaesthetics are used instead of fixing with belts, due to danger of abortion.

The examinations are started with the taking of an overall topogram which resembles a conventional two-dimensional

Figure 5 : Topogram of three rabbits with the level of othe kidneys on the right and the cross section of the m. *Longissimus dorsi* and the left kidney on the left.



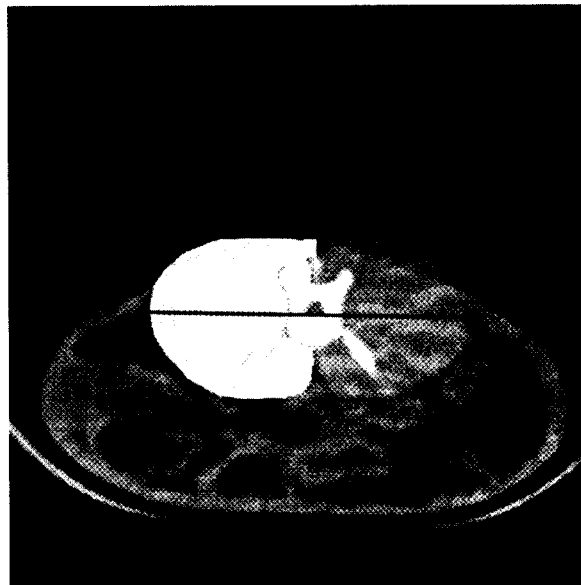
Figure 6. Upper topogram marked at the joints of the 2nd and 3rd (I) and 4th and 5th (II) lumbar vertebra



X-ray picture. In the topogram the anatomical levels of the later scans will be marked with horizontal lines.

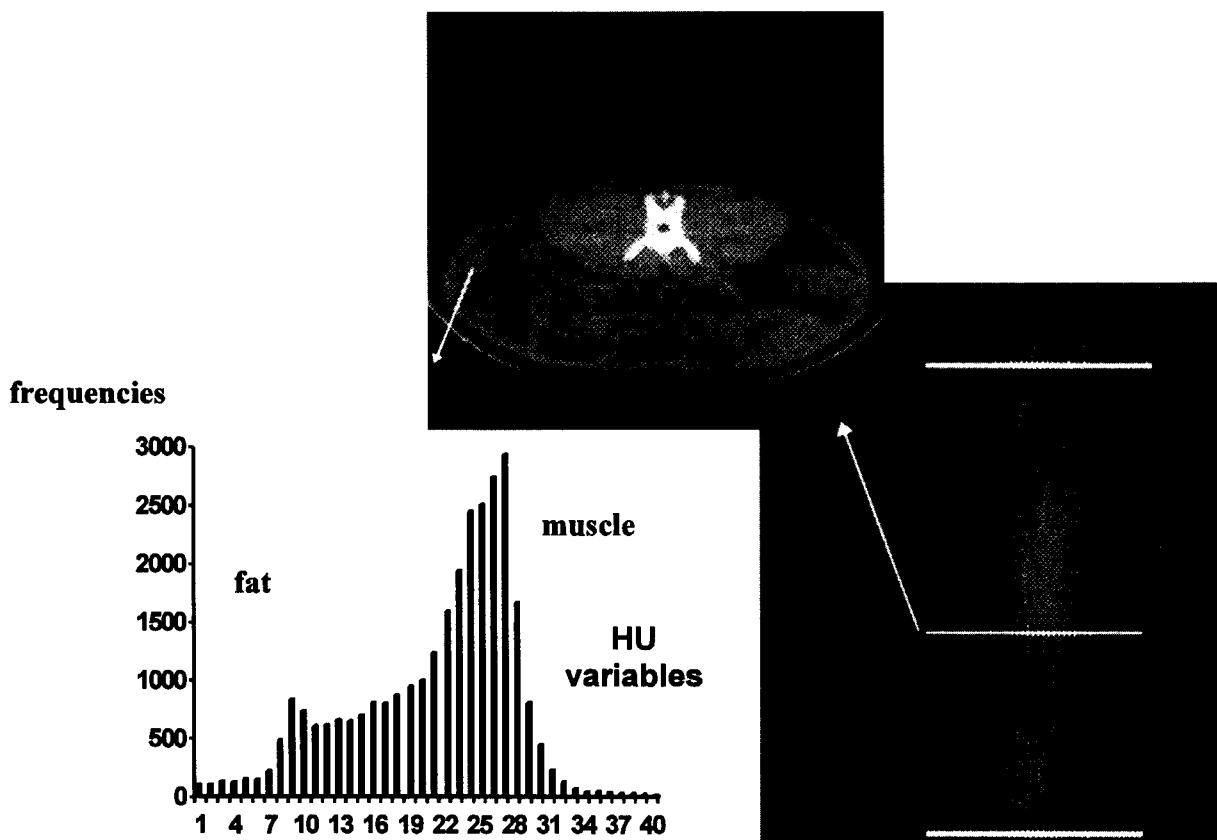
At the beginning the animals were scanned one by one, now we examine three rabbits at the same time (Fig. 5).

Figure 7 : Cross section of the *Longissimus dorsi* with marking its left side and maximum width.



The plexi container is suitable for taking both upper and side topograms and provides possibility for separate evaluation of rabbits. With this procedure the time consumption and the experimental costs are markedly reduced. Depending on the scan number, 12 to 36 rabbits can be examined per hour.

Figure 8 : Construction of the histogram (lower left) from the pixel density values of the marked area. The anatomical location of the scan (upper figure) is shown on the side topogram (lower right)



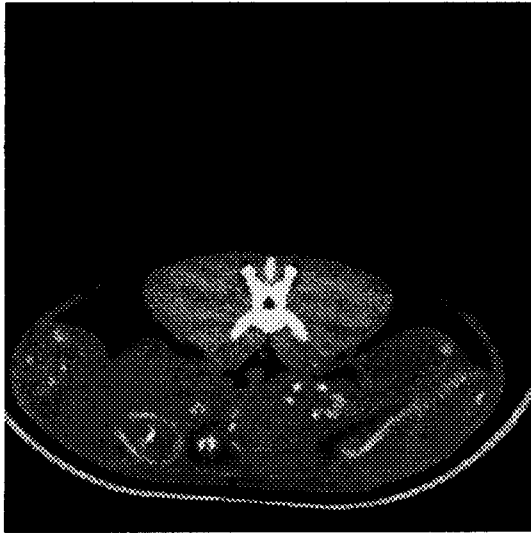


Figure 9 : Tomogram of a rabbit on the 28th day of pregnancy

Three different scanning methods were used. The first is based on fix anatomical points. This is used in the breeding program of the Pannon White rabbits, where the area of the cross section of the *m. longissimus dorsi* is measured between the 2nd and 3rd and between the 4th and 5th lumbar vertebra. Previously correlations (≈ 0.7) were found between the main carcass traits and the mean muscle surface of the cross section (SZENDRO *et al.*, 1992, 1994., ROMVARI *et al.*, 1995) (Fig. 6.).

The second approach is based on serial scans (pictures taken continuously with fixed distance between the consecutive scans). The most informative version is when the pictures cover the total body. In this case information is collected from the whole animal, then it is correlated with the results of the chemical analysis of the total body. On the right of Fig. 8. a side topogram is shown with markings (double line) at the level of *caput humeri* and the femoral-tibial articulation.

The third method utilises the fact that the distance between the two neighbouring scans depends on the size of

the rabbits. E.g. always 20 scans are taken from the 5th cervical vertebra to the head of the femur. This way scans with the same serial number represent the same anatomical points and, therefore, different-size animals can be compared. We use this method for the study of the growth of rabbits.

PICTURE EVALUATION

Two different approaches are used for the evaluation of CT pictures. The first one is based on the direct application of the CTPC software (CT post processing program for PC), developed by BERENYI and KÖVER (1991). With the help of it the pixels belonging to an optional HU interval are enhanced in the whole picture or in a part of it. Then the size of the indicated area is read directly in cm^2 . The tomogram on Fig. 7. was taken between the 4th and 5th lumbar vertebra. For better demonstration one side of the *m. longissimus dorsi* is marked with light patterns. The dark spots show the gas bubbles in the gastrointestinal tract. In addition to the cross section measurements distances can also be determined on the scans.

In the second approach the extreme density (HU) values (e.g. air or bone) are excluded and only those corresponding to muscle and fat are retained, i.e. the range from +200 to -200 in the Hounsfield scale. This range with its 400 value will be reduced to 40 intervals or Hounsfield variables (Huv), by the formation of an interval from 10 consecutive density values in the scale. These variables are used for statistical procedures, namely for as independent variables of prediction equations or for counting the frequency of density values falling into each interval in a scan or in a selected area and plotting histograms from the frequency data (Fig. 8.).

The histogram shows two peaks, one of them corresponds to the fat and the other to the muscle tissue.

With prediction equations based on the above mentioned Hu variables FEKETE *et al.* (1994) measured the total body fat, energy and protein content of New Zealand White rabbits. The applied MGLH stepwise procedure results in a medium to good accuracy in the prediction of total body composition.

FEKETE *et al.* (1993) have investigated nonpregnant and pregnant does on days 14, 21 and 28 of gestation. Fig. 9. shows a tomogram of a rabbit at four weeks of pregnancy where the scan was taken between the 3rd and 4th lumbar vertebra. The foetuses are shown on the lower part of the tomogram.

On Fig. 10. four histogram curves are shown, constructed from the density data of the scans across the foetus. The differences between tissue compositions are well visible. On day 14 of pregnancy a new peak is formed by the foetus (HUv=24) with maximum on the 28th day. The characteristic value of the muscle tissue (HUv=27) is higher than that of

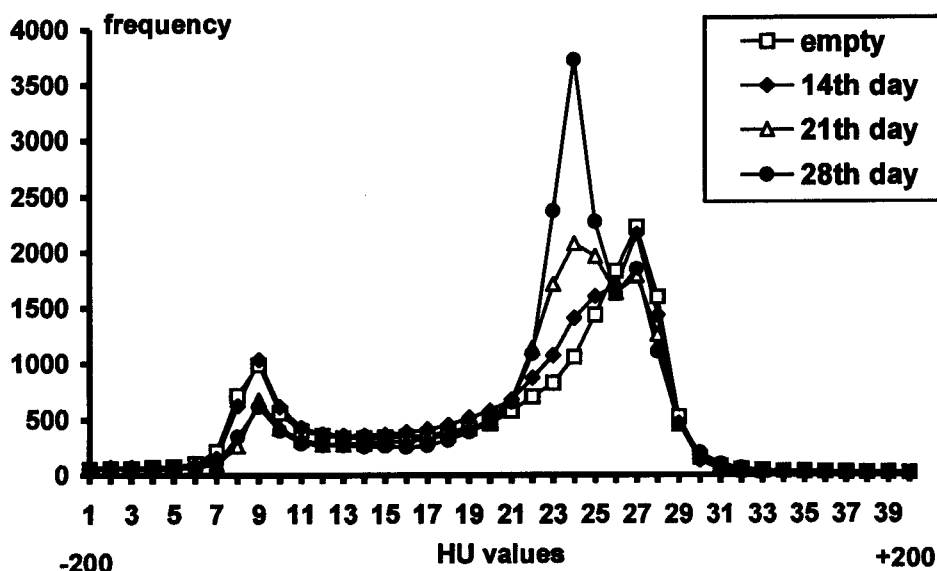


Figure 10 : Histograms of does at different stages of pregnancy

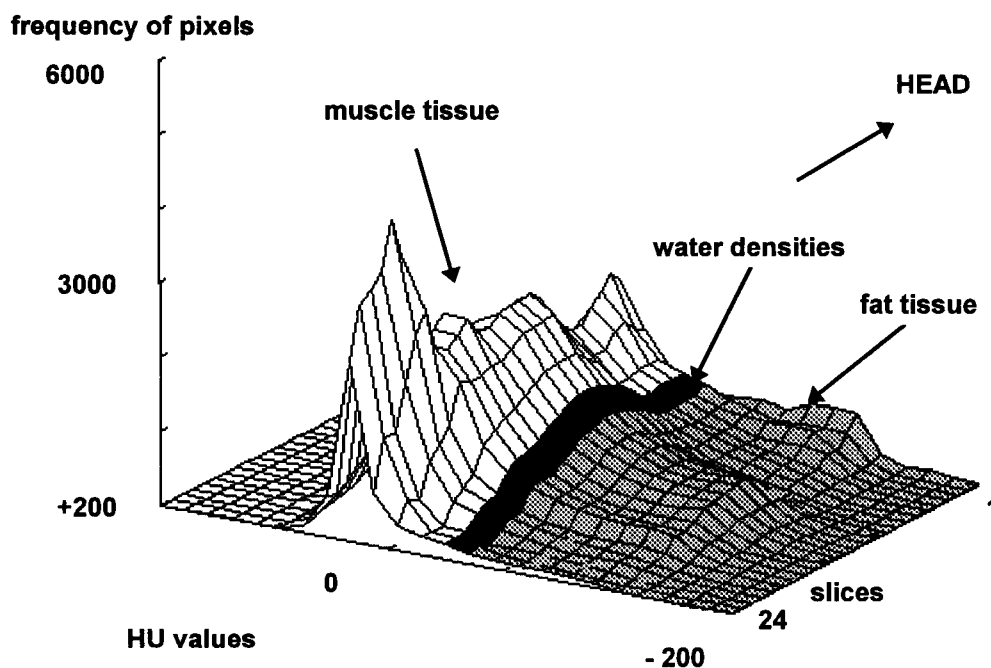


Figure 11 : 3-dimension histogram of rabbits of 3.5 kg

the foetus is because of the lower water content.

The CT pictures are taken by scan thicknesses ranging from 1 to 12 mm. It means that the picture-forming pixel can be considered a prism having a volume. So in the case of the examined scan or body interval we can define how large part of its whole volume falls into a HU interval. This provides the possibility to estimate the volume of a certain tissue.

Twenty-four tomograms, with 8 mm thickness and 20 mm distance between them, were taken serially from a 3.5 kg rabbit. Twenty scans were taken from the caput humeri to the caput femoris and four additional ones from the thighs. A three-dimension histogram was constructed from the density values of the pixels (Fig. 11; ROMVARI *et al.*, 1993). The serial numbers indicating the scans are shown on axis X and the density (HU) values ranging from -200 to +200 on axis Y. The whole range of 400 HU values was reduced to 40 equal intervals (see before), whose frequencies are indicated on axis Z.

The plot is dominated by a high, mountain-like ridge, which is due to the abundance of densities corresponding to muscle tissue. The ridge starts with the muscles of the shoulder (scans 1 to 3), followed by a depression at the level of the lungs (scans 4 to 8) and continuing with the m. longissimus dorsi and the thigh (the highest peak). Although there is no pure water in the body, water densities (0 HU) do occur and run parallel with the "muscle ridge" (black stained zone in Fig. 11.) The lower hill-side corresponds to the fat tissue. Accumulations of fat are indicated by three smaller elevations at the level of the shoulders (periscapular fat, scans 1 to 3), the kidneys (perirenal fat, scans 12 to 14) and the pelvis (pelvic fat, scans 18 to 19). Quantity of the tissues may be estimated by calculating the volume under the respective surfaces (ROMVARI *et al.*, 1994).

Received : January 15th, 1996.

Accepted : May 28th, 1996.

REFERENCES

- BERENYI E., KÖVER G., 1991. "CTPC", The CT post processing program.
- FEKETE S., HULLAR I., ROMVARI R., SZENDRO Z., SZAKALL I., 1993. Determination of nutrient requirement of rabbit by direct chemical analysis and computerised tomography. *In : Proc. Soc. Nutr. Physiol., Göttingen, Band 1. 61.*
- FEKETE S., HULLAR I., ROMVARI R., ANRASOFSZKY E., SZENDRO Z., 1994. [Complex study of the rabbits pregnancy]. 6. *Nyúlteny. Tud. Nap., Kaposvár.*
- HORN P., 1991. [New possibilities of the *in vivo* body analysis in meat-type animals' breeding, with special regards to the X-ray computerised tomography]. *Magy. Áo. Lapja*, 46, 3. 133-137.
- HOUNSFIELD G.N., 1980. Computed medical imaging. Nobel Lecture, Dec. 8, 1979. *J. Computer Assisted Tomography* 4, 665-674.
- ROMVARI R., SZENDRO Z., HORN P., 1993. Study on growth of muscle and fat tissue in rabbits by computerised tomography. *8th Symp. on Housing and Disease of Rabbits...*, Celle, 192-202.
- ROMVARI R., SZENDRO Z., HORN P., 1994. Study of growth of muscle and fat tissue by X-ray Computerised Tomography. *First International Conference on Rabbit Production in Hot Climates, Cairo.*
- ROMVARI R., SZENDRO Z., RADNAI I., BIRO-NEMETH E., 1995. The effect of the selection based on computer tomography on the carcass traits of Pannon White growing rabbits. *3rd Int. Symp. "Livestock Scientific Days", Bled, 253-259.*
- SKJERVOLD H., GRONSETH K., VANGEN O., EVENSE A., 1981. *In vivo* estimation of body composition by computerised tomography. *Z. Tierzüchtg. Züchtgsbiol.* 98. 77-79.
- SZENDRO Z., HORN P., KÖVER G., BERENYI E., RADNAI I., BIRO-NEMETH E., 1992. *In vivo* measurement of the carcass traits of meat type rabbits by X-ray computerised tomography. *5th World Rabbit Congress, Corvallis, 799-809.*
- SZENDRO Z., ROMVARI R., HORN P., RADNAI I., BIRO-NEMETH E., 1994. Selection for carcass traits of growing rabbits by CT. *First International Conference on Rabbit Production in Hot Climates, Cairo.*